

Case Report Article

Outpatient dental treatment under general anesthesia in children with cleft lip palate: case report

Ana Clara Suplicy Diogo Santos¹
Kimberly Tennyly Vonsovicz¹
Sheila de Carvalho Stroppa¹
Juliana Yassue Barbosa da Silva¹

Corresponding author:

Juliana Yassue Barbosa da Silva
Rua Professor Pedro Viriato Parigot de Souza, 5.300 – Campo Comprido
CEP 81280-330 – Curitiba – PR – Brasil
E-mail: juyassue@hotmail.com

¹ Department of Dentistry, Positivo University – Curitiba – PR – Brazil.

Received for publication: February 12, 2016. Accepted for publication: March 23, 2016.

Keywords: Dentistry;
children; general
anesthesia.

Abstract

Introduction and Objective: This study aimed to report the case of an eight-year-old patient with cleft lip and palate associated with undiagnosed syndrome presenting high level of carious lesions, difficulty on oral hygiene, no collaborative behavior and cariogenic diet. **Case report:** The patient underwent outpatient treatment for dental extraction and Atraumatic Restorative Treatment. Later at the following-up appointment, the child presented new active white spots and fractured restorations. Then, dental treatment under general anesthesia for amalgam restorations was indicated. **Conclusion:** We conclude that dental care under general anesthesia was an alternative treatment for the reported child in this clinical case that had a high prevalence of caries, cariogenic diet, loss of lip elasticity due to corrective surgeries, difficult access for oral hygiene and caregiver's fear to toothbrush near to the cleft.

Introduction

Cleft lip and palate (CLP)'s etiology occurs in intrauterine life. Many of cleft cases are related to multifactorial inheritance [12, 15, 25]. CLP can be caused by environmental factors such as use of alcohol, drugs, malnutrition, and ionizing radiation during pregnancy; a minor part is linked to a gene and/or altered chromosome [15]. CLP causes various functional difficulties and can affect speech, hearing, nutrition, and aesthetic and psychological problems, such as social integration. According to the severity of the cleft, it must have a multidisciplinary approach with speech therapy, psychology, dentistry, and different surgical interventions [13].

The clefts are divided into two groups according to their etiology: cleft lip or cleft lip and palate. As for cleft lip, at the seventh week of intrauterine life no fusion occurs between the frontal prominence and nasal processes with the maxillary process. Cleft palate occurs when there is no fusion of the bilateral processes in the midline, around the 12th week of embryonic development [29].

According to Spina *et al.* [30], clefts are classified according to their relationship with the incisive foramen, as follows: complete or incomplete pre-foramen incisive - when it is located before the foramen, but without going over it; transforamen incisive - the cleft surpasses the incisive foramen, affecting lip, alveolar ridge and palate complete or incomplete; post foramen incisive is located posterior to the incisive foramen. Both pre-foramen incisive and the transforamen incisive clefts can still be classified as unilateral, bilateral, and median. Furthermore, there are also rare facial clefts. Studies show the prevalence of cleft lip or cleft lip and palate in males, while cleft palate occurs more frequently in females [8].

Regarding the oral health of the individual with CLP, regardless of the type of cleft, there is greater risk of dental caries, periodontal disease, and malocclusion [3, 19, 35]. According to Dahllof *et al.* [14] and Hewson *et al.* [16], children with oral clefts have 3.5 times more surfaces of decayed teeth than children without clefts, more likely evident in primary teeth.

This fact is related to the presence of mutans microorganisms transmitted vertically from mother to child [7, 9, 20, 23], because of the close contact with the child's food and affection demonstrations, like kiss on the lips [33]. Furthermore, Wan *et al.* [33] attribute the increased risk to oral disease among individuals with cleft lip and palate to the anatomy of the region, time and frequency of carbohydrate intake in combination with the lack of education

of parents in diet and oral hygiene habits [2, 31]. There are also factors such as lack of information about the correct way of brushing in infants and children with clefts, trauma to administer the region affected by the cleft, difficult access around this area, decreased lip elasticity of the surgically repaired region, anatomy changed, and fear of intervention in the fissured region [14].

Children with clefts have difficulty of gaining weight, so parents are encouraged to offer food more often, thus leading to an accumulation of food debris in the mouth [10]. Some parents tend to make up for the up children's health by providing a diet that most pleases them [18]. In addition, some caregivers fail to understand the importance of oral care to avoid caries disease because they believe that surgical treatment is the most important, which ends up compromising the success of the treatment as a whole [10]. They end up leaving the oral health at the lower end on the scale of priorities and do not give due attention [11]. Bokhout *et al.* [6] reported that the highest rate of poor oral hygiene came from lower socioeconomic families as the highest socioeconomic class families followed the best recommendations on hygiene and more restricted sucrose consumption. There are several factors after reconstructive surgery that may act as obstacles to effective oral hygiene, making the children most likely to decay, such as remaining tissue, scar retraction, dental anomalies and persistent fistulas [11, 20].

Case report

An 8-year-old boy, GAD, was referred to Center for Cleft Lip and Palate (CAIF/AFISSUR) at two months of age without previous treatment. The boy had unilateral complete preforamen incisive cleft, congenital cardiomyopathy with small ventricular septal defect, mild pulmonary valve stenosis with a syndrome without defined diagnosis. He was unable to perform breastfeeding, so bottle feeding with artificial milk was prescribed. The boy was submitted to the corrective lip surgery at 1 year and 4 months-old, when he started to attend the Pediatric Dentistry Sector. At that moment, the mother was instructed regarding diet and oral hygiene. The boy already had a cariogenic diet rich in carbohydrates and used baby bottle with powdered milk (Ninho and Farinha Láctea, Nestlé) and milk flour before sleeping. The mother reported difficult in performing oral hygiene with toothbrush and she used gauze. The mother studied up to 8th grade of elementary school and the father up to

7th grade of elementary school, the family income was from 2 to three minimum wages.

The boy frequently attended the Pediatric Dentistry Sector receiving instruction on preventive oral care. Notwithstanding, the boy showed carious lesions that were properly restored. At 5 years-old, he still used baby bottle and the mother still reported difficult in oral hygiene due to the boy's lack of compliance. Accordingly, the boy was submitted to restorative and preventive dental treatment under general anesthesia. Then, the boy continued undergoing preventive following-up treatment.

At the beginning of 2015, the boy returned to the institution for following-up appointment and the difficult to perform oral hygiene was still present associated with the cariogenic diet and poor compliance. At clinical examination, new carious lesions were diagnosed and a new treatment was started.

After the reading and signing of the Free and Clarified Consent Form, the child was submitted to physical restraint aiming at his safe, and at assuring the treatment quality, due to his non-cooperative behavior (figure 1).

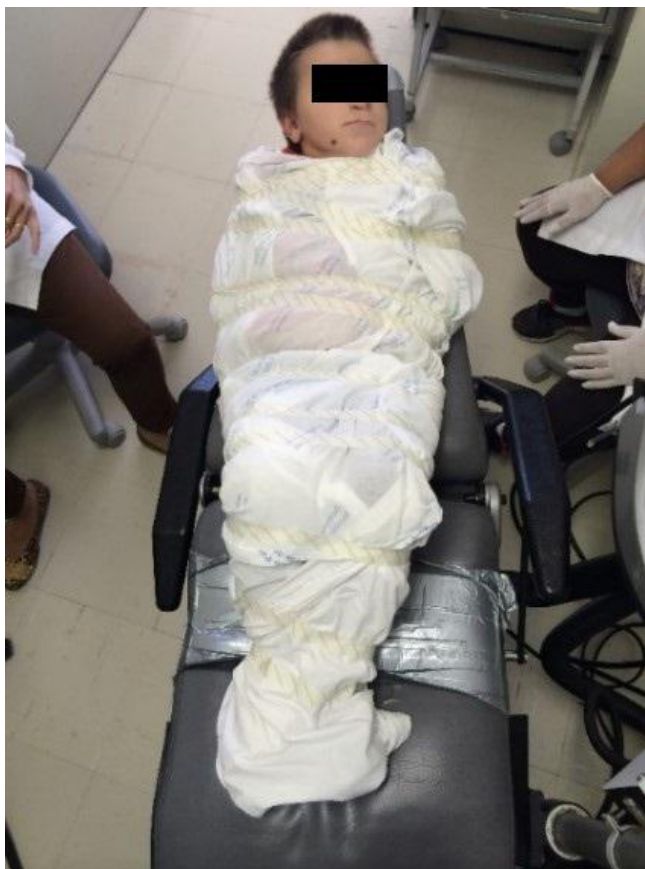

Figure 1 - Physical restraint

The tooth #64 showed endodontic fistula and deep large dentin carious lesion (figure 2), and thus extraction was indicated because of the impossibility of performing the radiographic examination due to noncompliance and impossibility to restore the tooth.

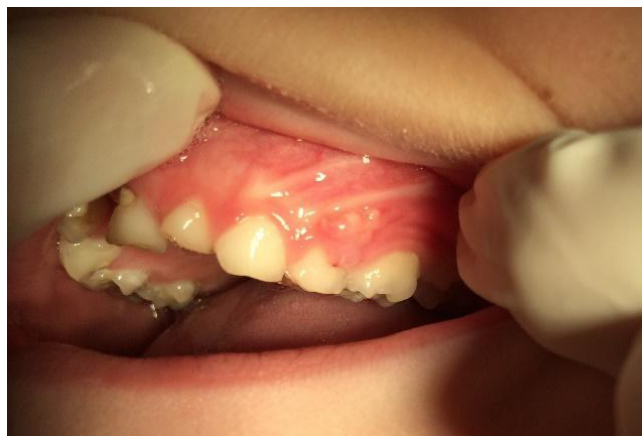

Figure 2 - Endodontic fistula of tooth #64

We performed the Atraumatic Restorative Treatment (ART) on teeth: #55 (occlusal surface), #54 (distal-occlusal surface); #61 (labial-mesial-palatal surface); #65 (occlusal surface), through removing the infected dentin and keeping the affected dentin followed by the restoration with conventional glass ionomer cement (GIC) (Fuji®). The child was submitted to dental prophylaxis with Robinson brush and sealant with glass ionomer cement (Fuji®) on teeth #16 and #26 (occlusal surfaces).

Also, we instructed the parents regarding oral hygiene (figure 3) with the aid of plaque disclosing solution (Replak®), followed by tooth brushing (figure 4), and application of fluoride varnish (Fluorniz®) on all teeth (figure 5).

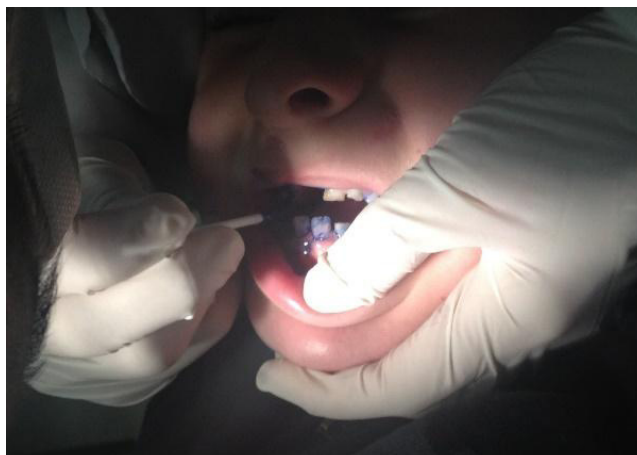


Figure 3 - Plaque disclosing

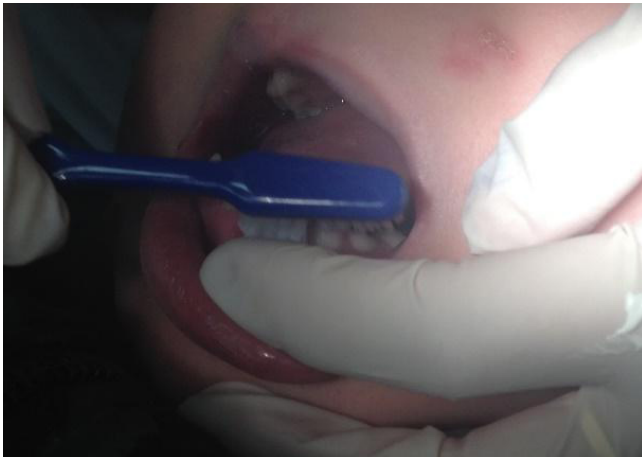

Figure 4 - Tooth brushing

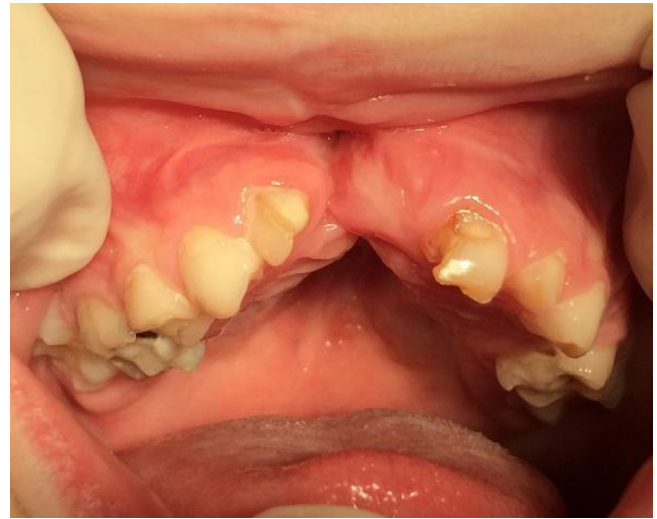


Figure 6 - Initial aspect of the maxillary teeth

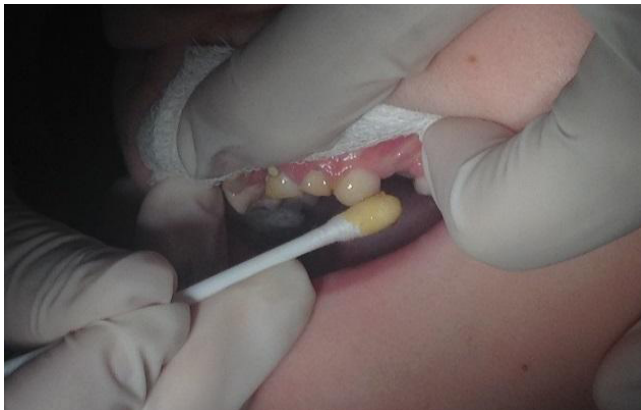

Figure 5 - Fluoride varnish application

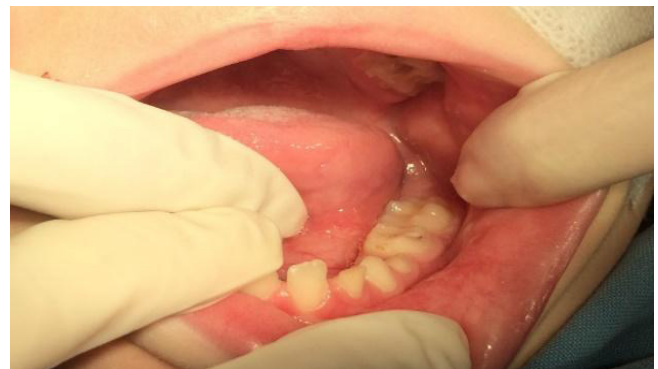

Figure 7 - Initial aspect of left mandibular teeth

After 3 months, the patient was reassessed to control oral health. The mother could not perform oral hygiene and cariogenic diet continued. At clinical examination, some GIC restorations fractured and the child had active white spots on other teeth (figures 6, 7, and 8). Furthermore, the mother reported that the boy should undergo a diet due to overweight.

Considering that, the treatment planning comprised dental treatment under general anesthesia at a hospital setting through nasal intubation (figure 9) to provide adequate space for dental treatment.

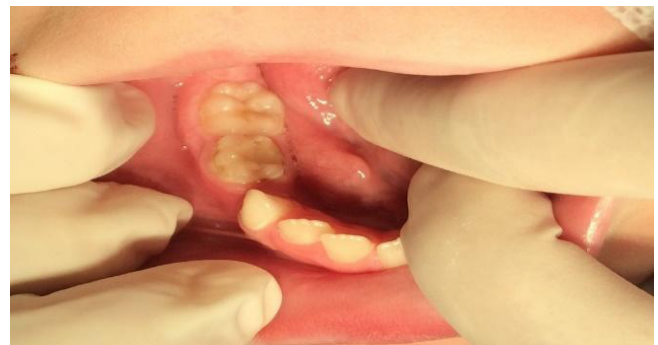

Figure 8 - Initial aspect of right mandibular teeth

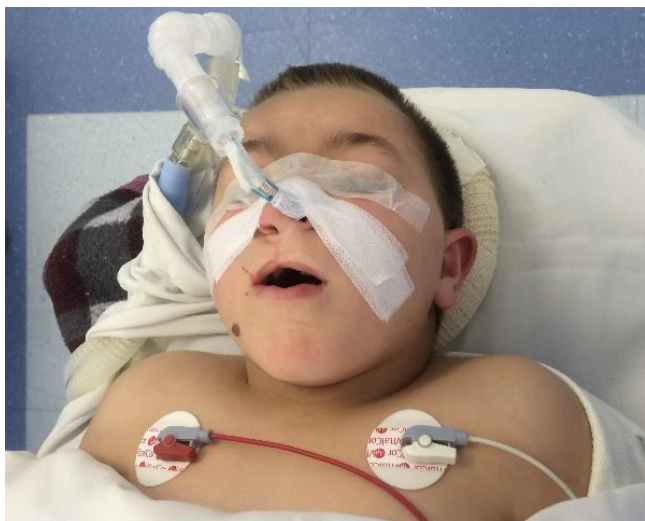

Figure 9 - Child under general anesthesia through nasal intubation

To prevent bacterial endocarditis, we prescribed antibiotic prophylaxis. Firstly, dental prophylaxis with Robinson brush and saline solution was executed to remove the plaque. Then, local anesthesia with mepivacaine + adrenalin 1:100.000 was applied aiming to obtain the vasoconstriction of the tissue surrounding tooth #74 prior to the extraction because of the carious lesion on occlusal, distal, lingual surfaces.

Amalgam restorations (Permite SDI®) were carried out on teeth: #55 (mesial-occlusal-distal-palatal), #54 (occlusal-distal, with GIC liner), #65 (occlusal-palatal), #75 (occlusal-buccal), because the GIC restorations had fractured and/or showed marginal leakage. Resin composite restoration (Charisma®) shade A1 was performed on tooth #52 (mesial-labial-palatal).

Tooth #46 received GIC sealant, and teeth #62 (labial), #61 (labial-mesial-palatal), and 85 (lingual) received GIC restorations. Because active white spots were present on teeth #73, #83, and #46, we applied fluoride varnish under dental anesthesia and the subsequent applications would be executed in dental chair. The other teeth also received fluoride varnish (figure 10). The finishing and polishing procedures were executed at outpatient setting.

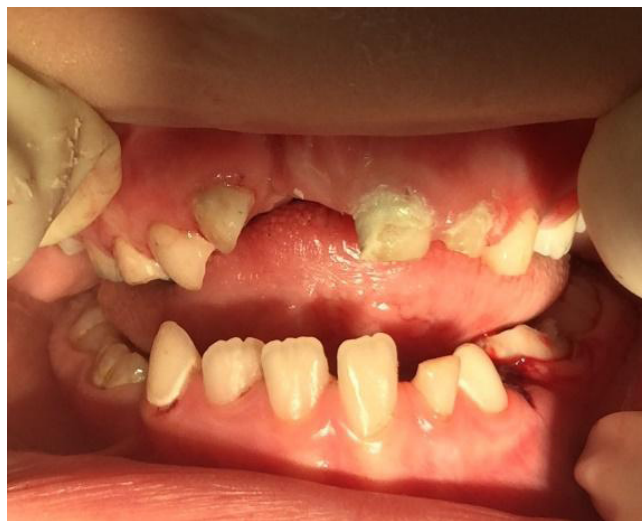

Figure 10 - Final immediate aspect

Discussion

In this case report, the child had cleft lip and palate and high caries activity at mixed dentition, agreeing with the studies of Dahllof *et al.* [14] and Hewson *et al.* [16], who reported a higher caries incidence in children with cleft lip and palate with deciduous teeth. On the other hand, the studies on permanent dentition evaluate and compare the caries prevalence in individuals with and without CLP. Lauterstein and Mendelsohn [22], Lucas *et al.* [24], and Hewson *et al.* [16] did not observed significant difference in the caries prevalence of these two groups. But, other studies [1, 4, 6, 14, 18] found greater risk for individuals with CLP.

Cheng *et al.* [11] noted that there are many factors that can contribute to the emergence of caries in primary teeth of children with CLP, such as difficulty of oral hygiene done by their caregivers, fear of hurting the area of the cleft, difficult access to the toothbrush near the cleft, because it is a sensitive area or even because some children have associated syndromes as in this case report, the patient is not collaborative, and the mother has difficulty in performing oral hygiene. According to Johnsen and Dixon [18] and Bokhout *et al.* [5], there is a higher percentage of dental caries in children with bilateral cleft lip and palate than in those with unilateral clefts. Moreover, the authors

also observed a greater prevalence in the teeth adjacent to the cleft and the first permanent molar because of hypoplastic enamel defects, resulting in a rough surface facilitating the adhesion and colonization of cariogenic bacteria. The anterior teeth may have greater accumulation of plaque in individuals with cleft lip and palate, as they have lower lip elasticity due to the surgical repair, in addition to brushing fear in the cleft region [14]. Concerning to oral hygiene, many studies [1, 25, 30, 32] reported worst results in individuals with cleft lip and palate.

In this present clinical case, the child had cariogenic diet, with daily and frequent ingestion of carbohydrates, sucrose, bottle feeding until 5 years of age. According to Ahluwalia *et al.* [1], sugars are fermented from starch intake and cause the appearance of tooth decay. The presence of cleft palate promotes food impaction, causing the food cake escapes to the nose and is regurgitated to the mouth, increasing the risk of caries because food is available for a longer time in the oral cavity for bacteria [11].

The family of this case report had low socioeconomic status, agreeing with the study of Bokhout *et al.* [6], who reported that children with clefts, with poor oral hygiene, and cariogenic diet were from families with monthly low income. The authors believe that families with higher incomes followed better the recommendations and restricted the consumption of cariogenic foods high in sucrose.

Johnsen [17] found that parents of children with clefts tend to abuse cariogenic diets to promote a form of satisfaction, because of the child's medical condition. Johnsen and Dixon [18] reported that the pattern of caries in children with clefts was similar to early childhood caries.

The study conducted by Saldūnaitė *et al.* [28], in Lithuania, concluded that the socioeconomic level and parental education has an influence on the prevalence of dental caries in children and had direct relation to the degree of concern that parents had in relation to oral hygiene of children. Accordingly, in the case reported herein, the mother studied up to 8th grade of elementary school, the father until the 7th grade and the family income was two to three minimum wages.

According to Roberts *et al.* [27], the initial attempts to manage the behavior of children involve some basic techniques as communicative orientation, say-show-and-do, voice control, nonverbal communication, positive reinforcement, distraction, the presence or absence of parents and

administration of nitrous/oxygen oxide. When these approaches are not capable of providing adequate treatment, advanced techniques can be applied, involving physical restraint, sedation, and general anesthesia [27].

As the child of this report presents intellectual disability and no collaborative behavior, we opted for the hospital dental treatment. According to Bengtson *et al.* [4], the general anesthesia, when properly used by professionals, reduces the risk of procedures and promotes the well-being of the patient and the work team.

For dental treatment under general anesthesia in children, both the hospital and the presence of an anesthesiologist during the procedure are required to check whether the patient is still unconscious and in the absence of anxiety, thus allowing dental treatment [4].

Conclusion

The case reported herein showed the failure of the outpatient treatment because of the great difficulty of the mother to perform oral hygiene, the lack of cooperation of the child, and the cariogenic diet. Thus, the treatment option with the best prognosis was planned for the hospital setting under general anesthesia, in which it can perform all the necessary procedures in the most effective way for the rehabilitation treatment of the child.

References

1. Ahluwalia M, Brailsford SR, Tarelli E, Golbert SC, Clark Dt, Barnard K et al. Dental caries, oral hygiene and oral clearance in children with craniofacial disorders. *J Dent Res.* 2004;83: 175-9.
2. Alves LM, Melo GG, Pereira JR, Cardoso MS. Prevalência de cárie em portadores de fissura labiopalatais atendidos no Instituto Materno Infantil de Pernambuco. *Odontol Clín-Cientif.* 2004;3:57-60.
3. Batista LRV, Triches TC, Moreira EAM. Desenvolvimento bucal e aleitamento materno em crianças com fissura labiopalatal. *Rev Paul Pediatr.* 2011;29:674-9.
4. Bengtson CRG, Bengtson NG, Bengtson AL, Pinheiro SL, Mendes FM. O uso da anestesia geral em odontopediatria. *Rev Inst Ciênc Saúde.* 2006;24(4):319-25.

5. Bokhout B, Hofman FX, van Limbeek J, Kramer GJ, Prahl Andersen B. Incidence of dental caries in the primary dentition in children with a cleft lip and/or palate. *Caries Res.* 1997;31:8-12.
6. Bokhout B, Hofman FX, van Limbeek J, Kramer GJ, Prahl Andersen B. Increased caries prevalence in 2.5-year-old children with cleft and/or palate. *Eur J Oral Sci.* 1996;104:518-22.
7. Bokhout B, Van Loveren C, Hofman FX, Buijs JF, Van Limbeek J, Prahl Andersen B. Prevalence of streptococcus mutans and lactobacilli in 18-month-old children with cleft lip and/or palate. *Cleft Palate Craniofac J.* 1996;33:424-8.
8. Bonaiti C, Briard ML, Feingold J, Pavy B, Psaume J, Migne-Tufferaud G et al. An epidemiological and genetic study of facial clefting in France. I. Epidemiology and frequency in relatives. *J Med Genet.* 1982;19:8-15.
9. Bonecker MJS, Ardenghi TM, Trindade CP, Cury P. Transmissão vertical da streptococcus mutans e suas implicações. *JBP Rev Ibero Am Odontopediatria Odontol Bebê.* 2004 May-Jun;7(37):297-303.
10. Byan Z, Du M, Bedi R, Holt R, Jin H, Fan M. Caries experience and oral health behavior in Chinese children with cleft lip and/or palate. *Pediatr Dent.* 2001;23:431-4.
11. Cheng LL, Moor SL, Ho CTC. Predisposing factors to dental caries in children with cleft lip and palate: a review and strategies for early prevention. *Cleft Palate Craniofac J.* 2007;44(1):67-78.
12. Chung CS, Bixler D, Watanabe T, Koguchi H, Fogh-Andersen P. Segregation analysis of cleft lip with or without cleft palate: a comparison of Danish and Japanese. *Am J Hum Genet.* 1986;39:603-11.
13. Dixon MJ, Marazita ML, Beaty TH, Murray JC. Cleft lip and palate: understanding genetic and environmental influences. *Nat Rev Genet.* 2011 Mar;12(3):167-78.
14. Dahllof G, Ussisso-Joandi R, Ideberg M, Modeer T. Caries, gingivitis, and dental abnormalities in preschool children with cleft lip and/or palate. *Cleft Palate J.* 1989;26:233-7.
15. Fraser FC. The genetics of cleft lip and cleft palate (review). *Am J Hum Genet.* 1970;22:336-52.
16. Hewson AR, McNamara CM, Foley TF, Sandy JR. Dental experience of cleft affected children in the west of Ireland. *Int Dent J.* 2001;51:73-6.
17. Johnsen DC. Dental caries patterns in preschool children. *Dent Clin North Am.* 1984;28:3-20.
18. Johnsen DC, Dixon M. Dental caries of primary incisors in children with cleft lip and palate. *Cleft Palate J.* 1984;21:104-9.
19. Kirchberg A, Treide A, Hemprich A. Investigation of caries prevalence in children with cleft lip, alveolus, and palate. *J Craniomaxillofac Surg.* 2004;32:216-9.
20. Kohler B, Bratthall D. Intrafamilial levels of Streptococcus mutans and some aspects of the bacterial transmission. *Scand J Dent Res.* 1978;86:35-42.
21. Lai MC, King NM, Wong HM. Abnormalities of maxillary anterior teeth in Chinese with cleft lip and palate. *Cleft Palate Craniofac J.* 2009;46:58-64.
22. Lauterstein AM, Mendlesohn M. An analysis of the caries experience of 285 cleft palate children. *Cleft Palate J.* 1964;1:314-9.
23. Li Y, Caufield PW. The fidelity of initial acquisition of mutans streptococci by infants from their mothers. *J Dent Res.* 1995;74:681-5.
24. Lucas VS, Gupta R, Ololade O, Gelbier M, Roberts GJ. Dental health indices and caries associated microflora in children with unilateral cleft lip and palate. *Cleft Palate Craniofac J.* 2000;37:447-52.
25. Melnick M, Bixler D, Fogh-Andersen P, Conneally PM. Cleft lip ± cleft palate: an overview of the literature and an analysis of danish cases born between 1941 and 1968. *Am J Med Genet.* 1980;6:83-97.
26. Paul T, Brandt RS. Oral and dental health status of children with cleft lip and/or palate. *Cleft Palate Craniofac J.* 1998;35:329-32.
27. Roberts JF, Curzon ME, Koch G, Martens LC. Review: behavior management techniques in pediatric dentistry. *Eur Arch Paediatr Dent.* 2010;11:16-74.
28. Saldūnaitė K, Bendoraitienė EA, Slabšinskienė E, Vasiliauskienė I, Andruskevicienė V, Zūbienė J. The role of parental education and socioeconomic status in dental caries prevention among Lithuanian children. *Medicina.* 2014;50:156-61.

29. Saxén I. Cleft lip and palate in Finland: parental histories, course of pregnancy and selected environmental factors. *Int J Epidemiol.* 1974;3:263-70.
30. Spina V, Psillakis JM, Lapa FS, Ferreira MC. Classificação das fissuras lábio-palatinas: sugestões de modificação. *Rev Hosp Clín Fac Med S Paulo.* 1972;27:5-6.
31. Turner C, Zagirova AF, Frolova LE, Courts FJ, Williams WN. Oral health status of Russian children with unilateral cleft lip and palate. *Cleft Palate Craniofac J.* 1998;35:489-94.
32. Vasconcelos NP, Melo P, Gavinha S. Estudo dos fatores etiológicos das cáries precoces da infância numa população de risco. *Rev Port Estomatol Cir Maxilofac.* 2004;45:69-77.
33. Wan AK, Seow WK, Purdie DM, Bird PS, Walsh LJ, Tudehope DI. A longitudinal study of *Streptococcus mutans* colonization in infants after tooth eruption. *J Dent Res.* 2003;82:504-8.
34. Wong FWL, King NM. The oral health of children with clefts-a review. *Cleft Palate Craniofac J.* 1998;35:248-54.
35. Zhu WC, Xiao J, Liu Y, Wu J, Li JY. Caries experience in individuals with cleft lip and/or palate in China. *Cleft Palate Craniofac J.* 2010;47:43-7.