

Case Report Article

Le Fort II osteotomy for medium-face fracture sequel correction

Thalyta Verbicaro¹
Aline Monise Sebastiani^{1, 2}
Jennifer Tsi Gerber¹
Bruno Viezzer Fernandes²
João Cesar Zielak¹
Rafaela Scariot^{1, 2}
Leandro Eduardo Klüppel^{1, 2}

Corresponding author:

Thalyta Verbicaro
Positivo University – Dentistry Department
Prof. Pedro Viriato Parigot de Souza, 5300 St – Campo Comprido
CEP 81280-330 – Curitiba – PR – Brasil
E-mail: thalyta.verbicaro@up.edu.br

¹ School of Health and Biological Sciences, Positivo University – Curitiba – PR – Brazil.

² Oral and Maxillofacial Surgery Department, Federal University of Paraná – Curitiba – PR – Brazil.

Received for publication: January 19, 2018. Accepted for publication: May 30, 2018.

Keywords:

orthognathic surgery;
osteotomy Le Fort;
multiple trauma.

Abstract

Introduction: Fractures should be treated by a multi-professional team to minimize sequels. The surgery aims to establish a good maxillary, mandibular relationship to improve mastication and phonetics and may benefit esthetics. **Objective:** to report the surgical procedure with Le Fort II osteotomy for correction of class III dentofacial deformity and the nasomaxillary deficiency caused by trauma. **Case report:** Patient victim of aggression for 10 years suffered a Le Fort II fracture. The fracture was not treated and the patient developed a severe anteroposterior defect of the nasomaxillary complex and Class III occlusion. The surgery for correcting deformities was performed with the bicoronal, lower eyelid and intraoral accesses. Le Fort II pyramidal osteotomy was performed with a piezoelectric motor to advance 7 mm the nasomaxillary complex. **Conclusion:** Le Fort II osteotomy is considered satisfactory for advancing the nasomaxillary complex, improving the patient's psychosocial function and development.

Introduction

Facial trauma has a growing incidence in recent years due to car accidents, sports accidents, and aggressions. Trauma patients should receive multi-professional treatment to avoid sequels with temporary or definitive limitations. Also, team agility and patient collaboration are critical in decreasing morbidity [6, 12].

Untreated facial fractures usually cause malocclusion, impair mastication, phonetics and facial harmony. These defects can be treated later with corrective surgeries establishing a favorable maxillary, mandibular relationship [12].

The treatment plan and the surgical technique are defined based on facial analysis and assessment of facial discrepancy. Le Fort II osteotomy is indicated for nasomaxillary hypoplasias and correction of retrusion of the nasomaxillary complex, allowing the advancement of the middle third of the face [9-11, 13].

Mobilization of the maxilla was first performed by Wassmund in 1927 to correct the malocclusion. He used the osteotomy drawings described by Le Fort in 1901. Subsequently, Obwegeser fully

mobilized the maxilla, allowing vertical and sagittal adjustments [9].

The objective of this study is to report the surgical procedure with Le Fort II osteotomy for correction of class III dentofacial deformity and the nasomaxillary defect caused by trauma.

Case report

The patient was a victim of aggression ten years ago with Le Fort II fracture. The treatment was not performed, and the patient developed respiratory difficulty, masticatory and with aesthetic complaint caused mainly by the anteroposterior deficiency of the middle third of the face and by the sinking of the nasal frontal region.

The patient sought care to improve chewing, phonetics and aesthetics. At the clinical examination, the patient presented a deficiency of nasomaxillary complex, concave profile, adequate cervical distance, slightly planned zygomatic region (figure 1) and class III occlusion, with a 3-mm right deviation from the midline of the maxilla (figure 2).

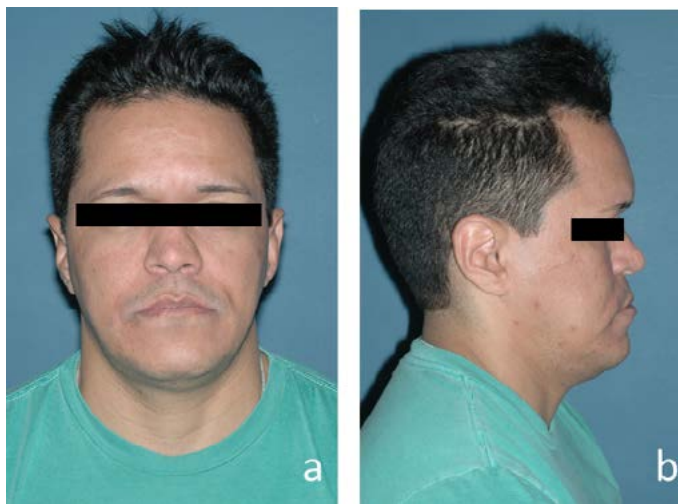

Figure 1 - Extra oral preoperative images: A) frontal photograph showing a slightly planned zygomatic region; B) lateral photograph showing a deficiency of the nasomaxillary complex and concave profile

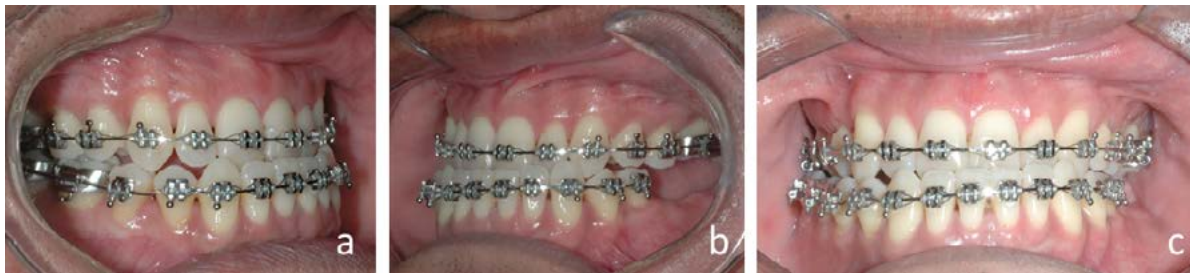

Figure 2 - Intraoral pre-operative images showing a class III occlusion: A) right lateral view from dental occlusion; B) left lateral view from dental occlusion; C) frontal view from dental occlusion, with 3-mm right deviation from the midline of the maxilla

In the imaging examination, it is possible to observe the anteroposterior bone defect of the nasomaxillary complex and the occlusal class III relation (figure 3). The patient began treatment with the orthodontic preparation to align and level the teeth and to eliminate the dental compensations, allowing the surgical repositioning of the complex.

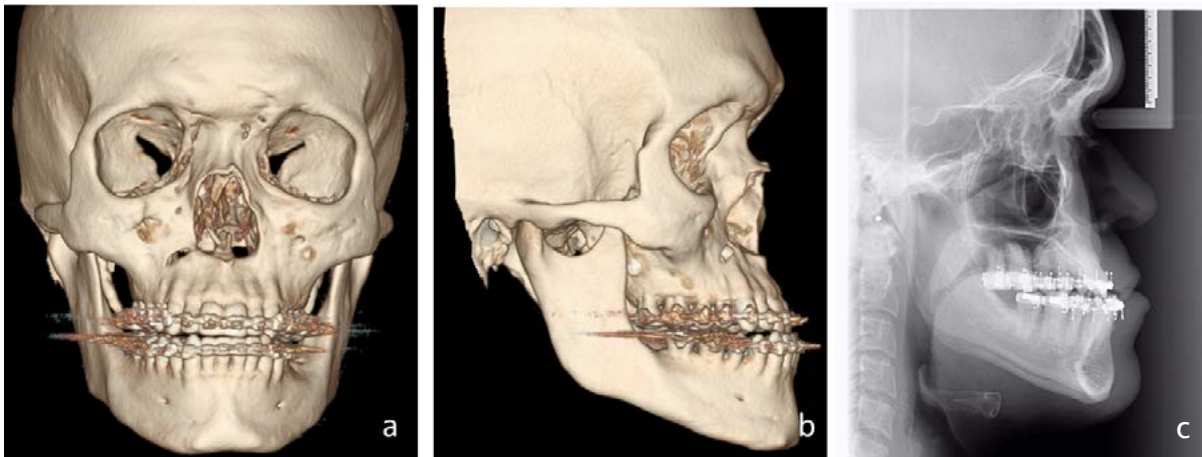


Figure 3 - Pre-operative imaging: A) frontal 3D reconstruction from CT; B) lateral 3D reconstruction from CT; C) lateral cephalometric radiograph showing an anteroposterior bone defect of the nasomaxillary complex and occlusal class III relation

In the planning, a lateral cephalometric radiograph was used to evaluate the surgical movement. The patient underwent computerized tomography (CT) of the face and DICOM (Digital Imaging and Communications in Medicine) images were used to make a prototype of the facial skeleton. Model surgery was performed in the prototyping piece to simulate the 7 mm advancement of the nasomaxillary region.

The surgical procedure was performed under general anesthesia, with nasotracheal intubation. The accesses used were bicoronal, lower eyelid and intraoral (figure 4). The Le Fort II pyramidal osteotomy was performed with a piezoelectric motor (NSK, São Paulo, SP, Brazil) and with a drill (Kavo, São Paulo, SP, Brazil), the nasomaxillary complex was mobilized with Rowe forceps for an advancement of 7 mm. After the maxillary-mandibular block, fixation was performed with plates and screws of the 2.0 system (Orthoface, Curitiba, PR, Brazil) on the zygomatic pillar and in the nasal frontal suture. A titanium screen (Orthoface, Curitiba, PR, Brazil) was placed in the nasal region to improve the contour and to cover the plate and screws.

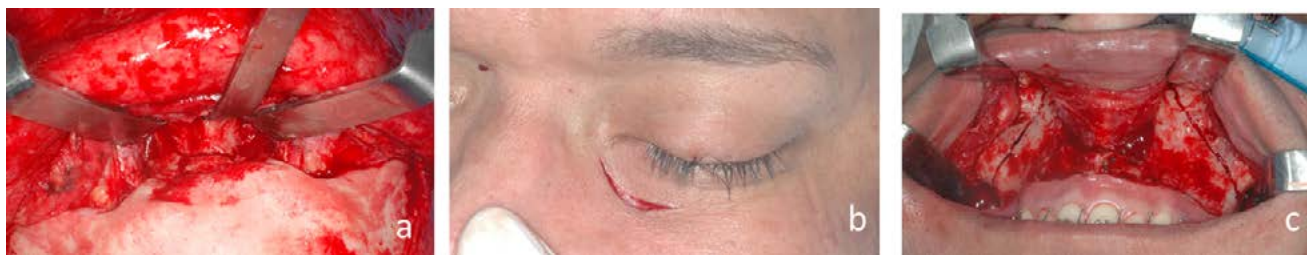

Figure 4 - Surgical procedure: A) bicoronal access; B) lower eyelid access; C) intra oral access to perform Le fort II osteotomy

In the one month postoperative consultation, it was possible to observe the progress of the nasomaxillary complex and the improvement in the patient's profile (figure 5). In the three-dimensional postoperative tomographic reconstruction and the lateral cephalometric radiograph, it is possible to observe the advancement and the class I occlusion (figure 6).

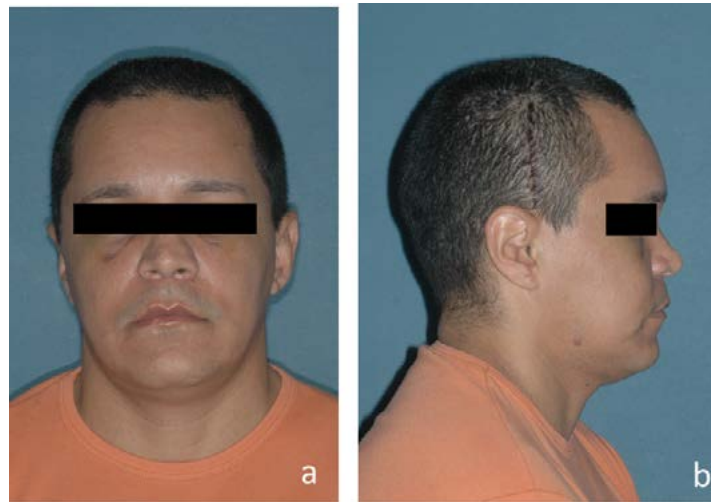

Figure 5 - One month post-operative images: A) frontal photograph; B) right lateral photograph

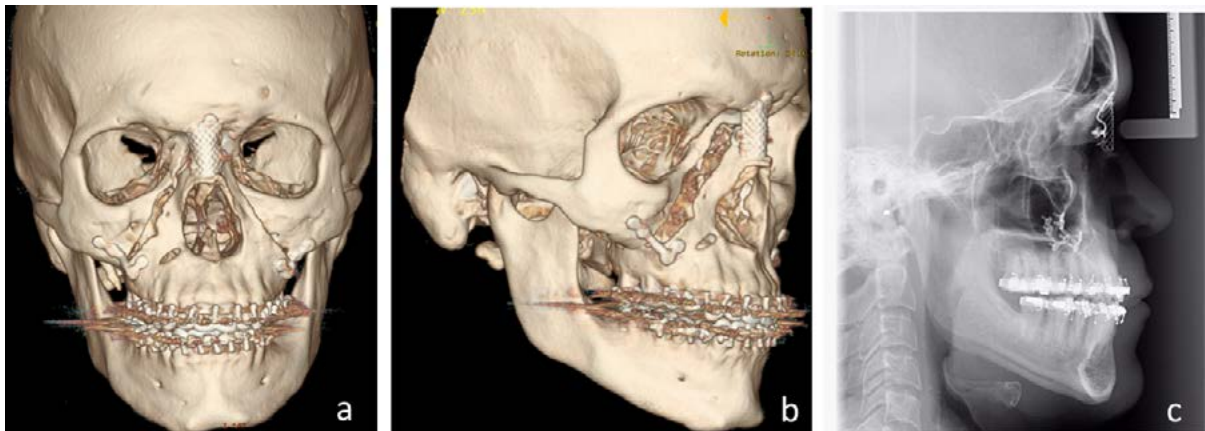


Figure 6 - One month post-operative imaging: A) frontal 3D reconstruction from CT, with a possible visualization of the fixation material; B) lateral 3D reconstruction from CT, showing the advancement of the maxillary nasal complex; C) lateral cephalometric radiograph of the profile shows a class I occlusal relation

Discussion

In the case of trauma, several body systems are affected, and the patient is received in an emergency care that ensures the maintenance of the airways. Soft tissue injuries are initially treated for hemostasis, and fractures are treated later when they do not pose a risk to the patient's life [12].

Le Fort II and III fractures may be associated with severe intracranial lesions, even without changed consciousness. Therefore, these patients should be assisted by a multi-professional team and monitored until hospital discharge [1].

Surgical treatment of complex facial trauma is indicated to minimize functional and esthetic deficit and to avoid that the emotional consequences are definitive with social impact. The sequels of untreated trauma vary according to the severity of the accident [6].

Orthognathic surgery with stable internal fixation is indicated for the treatment of dentofacial deformities caused by developmental hypoplasia and for the late treatment of defects caused by trauma. Its purpose is to return the function with an acceptable occlusion and facial harmony. In cases of deficiency of the middle third of the face, the Le Fort II osteotomy may be indicated [7, 8, 10].

Orthognathic surgery with Le Fort I osteotomy associated with rhinoplasty may be proposed for the treatment of nasomaxillary dipping as well as Le Fort II. The rhinoplasty graft has autogenous or alloplastic origin and should preserve respiratory quality and natural appearance [4].

Osteogenic distraction may also be indicated to advance the middle third of the face, especially in cases where the overjet is accentuated. This technique is considered safe, predictable and dispenses with rigid internal fixation, not requiring

grafting and avoiding spaces vulnerable to infection. In cases of internal distractors, the disadvantage of this technique on orthognathic surgery is a second surgical time [2, 3].

The use of biomodel from prototyping benefits the treatment since it assists in the diagnosis and the surgical planning. This technology is used for surgery planning because it accurately reproduces the anatomy that will be operated. These models facilitate communication with the patient, can shorten the surgical time, improve visualization and allow simulation of surgical movement [14]. In this case, these pieces were fundamental for the simulation of the nasomaxillary complex advancement.

The osteotomy for the mobilization of the nasomaxillary complex was performed with a piezoelectric motor. This technology was developed in Italy in 2007, and its main advantages are: it does not overheat the bone, it does not injure soft tissues, it has high accuracy and safety [5].

Conclusion

The Le Fort II osteotomy is favorable for the advancement of the nasomaxillary complex and correction of class III malocclusion. The result is considered satisfactory since there was a functional improvement with aesthetic and psychosocial benefit.

References

- Bellamy JL, Mundinger GS, Reddy SK, Flores JM, Rodriguez ED, Dorafshar AH. Le Fort II fractures are associated with death: a comparison of simple and complex midface fractures. *J Oral Maxillofac Surg.* 2013 Sep;71(9):1556-62.
- Cheung LK, Lo J. Distraction of Le Fort II osteotomy by intraoral distractor: a case report. *J Oral Maxillofac Surg.* 2006 May;64(5):856-60.
- Figueroa AA, Polley JW. Clinical controversies in oral and maxillofacial surgery: part two. External versus internal distraction osteogenesis for the management of severe maxillary hypoplasia: external distraction. *J Oral Maxillofac Surg.* 2008;66(12):2598-604.
- Foda HM. Rhinoplasty for the multiply revised nose. *Am J Otolaryngol.* 2005 Jan-Feb;26(1):28-34.
- Hara S, Mitsugi M, Kanno T, Nomachi A, Kawakami S, Tatemoto Y. Endoscopically assisted intraoral modified Le Fort osteotomy. *J Oral Maxillofac Surg.* 2003 Feb;71(2):e93-103.
- Iida S, Kogo M, Sugiura T, Mima T, Matsuya T. Retrospective analysis of 1502 patients with facial fractures. *Int J Oral Maxillofac Surg.* 2001;30:286-90.
- Keller EE, Sather AH. Intraoral quadrangular Le Fort II osteotomy. *J Oral Maxillofac Surg.* 1987 Mar;45(3):233-5.
- Song H, Park MC, Lee IJ, Park DH. Correction of infraorbital and malar deficiency using costal osteochondral graft along with orthognathic surgery in Crouzon syndrome. *J Craniofac Surg.* 2014 Sep;25(5):e449-51.
- Sullivan SM. Le Fort I osteotomy. *Atlas Oral Maxillofacial Surg Clin N Am.* 2016;24:1-13.
- Tahiri Y, Taylor J. An update on midface advancement using Le Fort II and III distraction osteogenesis. *Semin Plast Surg.* 2014 Nov;28(4):184-92.
- Urban SD, Rebellato J, Keller EE. Intraoral maxillary quadrangular Le Fort II osteotomy: a long-term follow-up study. *J Oral Maxillofac Surg.* 2004 Aug;62(8):943-52.
- Vrinceanu D, Banica B. Principles of surgical treatment in the midface trauma - theory and practice. *Maedica (Buchar).* 2014 Dec;9(4):361-6.
- Vu DD, Tiwana P. Le Fort II and Le Fort III osteotomies. *Atlas Oral Maxillofacial Surg Clin N Am.* 2016;24:15-25.
- Winder J, Bibb R. Medical rapid prototyping technologies: state of the art and current limitations for application in oral and maxillofacial surgery. *J Oral Maxillofac Surg.* 2005;63:1006-15.