

## Original Research Article

# Evaluation of the cross-section area and flexural strength of fractured rat femurs repaired with titanium and absorbable plates fixation

Paola Corso<sup>1</sup>  
Gabrielle Kuchar<sup>1</sup>  
Luana Bonetto<sup>1</sup>  
Maurício Perussolo<sup>1</sup>  
Leonardo Fernandes da Cunha<sup>2</sup>  
Carla Castiglia Gonzaga<sup>1</sup>  
Rafaela Scariot<sup>3</sup>  
Aline Sebastiani<sup>3</sup>

### Corresponding author:

Paola Corso  
Rua Professor Pedro Viriato Parigot de Souza, 5.300 – Campo Comprido  
CEP 81280-330 – Curitiba – PR – Brasil  
E-mail: paolafcorso@gmail.com

<sup>1</sup> School of Health Science, Dentistry, Universidade Positivo – Curitiba – PR – Brazil.

<sup>2</sup> School of Health Sciences, Department of Dentistry, Universidade de Brasília – Brasília – DF – Brazil.

<sup>3</sup> Department of Stomatology, Universidade Federal do Paraná – Curitiba – PR – Brazil.

*Received for publication: February 22, 2021. Accepted for publication: March 12, 2021.*

### Keywords:

traumatology; femoral fractures; fracture fixation, internal; absorbable implants; titanium.

### Abstract

**Objective:** To compare the mechanical strength of rat femur after complete fracture treated absorbable and titanium plates and screws. **Material and methods:** A total of 10 male Wistar rats were divided in two groups, according to the femoral fracture fixation: titanium (TG) or absorbable plates (AG). A femur fracture was performed in one side after the corresponding plates of each group were adapted and fixated. The euthanasia occurred with 90 days postoperative, and the fracture femurs were compared with the opposite side control group (CG) in the mechanical tests, through the three-point bending flexural test, and the flexural strength was calculated. Using a digital caliper, the cross-section area was calculated. Data were submitted to the statistical analysis, with the significance level of 0.05. **Results:** The cross-section in the AG was higher than CG ( $p < 0.001$ ). With respect of flexural strength, the AG was similar with CG ( $p = 1.00$ ), and the TG showed lower flexural strength when compared with CG ( $p = 0.006$ ) and with AG ( $p = 0.042$ ). **Conclusion:** The group fixed with absorbable plates demonstrated increased cross-section area compared to the control group and increased flexural strength compared to the group fixed with titanium plates.

## Introduction

Bone fractures are mechanically defined as the loss of bone tissue continuity or as the result of fatigue in the structure of a bone. It is the most common in large-organ traumatic injuries to humans [5]. The fracture healing represents a complex process that mimic parts of the embryological development of the bone framework. Sometimes, osteosynthesis materials are necessary to create the circumstances for bone regeneration [12] because bone repair depends on fractured segments proximity [10]. The stability of the fixation and the immobilization of the fracture affect the revascularization and the patterns of skeletogenic stem cell differentiation into chondrocytes or osteoblasts [5].

In treatment of facial fractures, titanium plates and screws are considered as the gold standard to internal fixation, due their properties of high biocompatibility, resistance to corrosion, minimal scatter in computerized tomography scanning and compatibility with plain radiography and with the use of magnetic resonance imaging [3]. However, problems like the presence of titanium particles in the overlying soft tissues and occasionally in the regional lymph nodes, thermal conductivity, possibility of maxillary sinusitis, unacceptable palpability, allergic hypersensitivity, chemical carcinogenesis, infection around the hardware and the limitation in growing patients have been described [3]. In some cases, these alterations require the removal of the titanium plates or screws after the consolidation of bone segments.

To overcome the disadvantages of this conventional titanium system, a new class of materials, the absorbable polymers, was developed for use in internal fixation. The great advantage of this type of fixation is the resorption of the material after having fulfilled the function of stabilizing the fragments fractured during the bone repair phase [2]. This allows the use of internal fixation with greater safety in children without necessity of a second surgery to remove the material or to interfere in bone growth. In addition, it presents as characteristics: promotion of direct contact with the bone, mechanical strength close to the cortical bone, bioactive and biodegradable properties [13].

Although the absorbable plaques seemingly offer clinical advantages over the metal plates, concern remains about the stability of the fixation. In this context, to test different materials in bone fracture repair, models of femur fracture in rats have been performed [14]. Thus, the aim of this study was to

compare the mechanical strength of rat femur after complete fracture treated with 2-mm absorbable plates and screws and with 2-mm titanium plates and screws.

## Material and methods

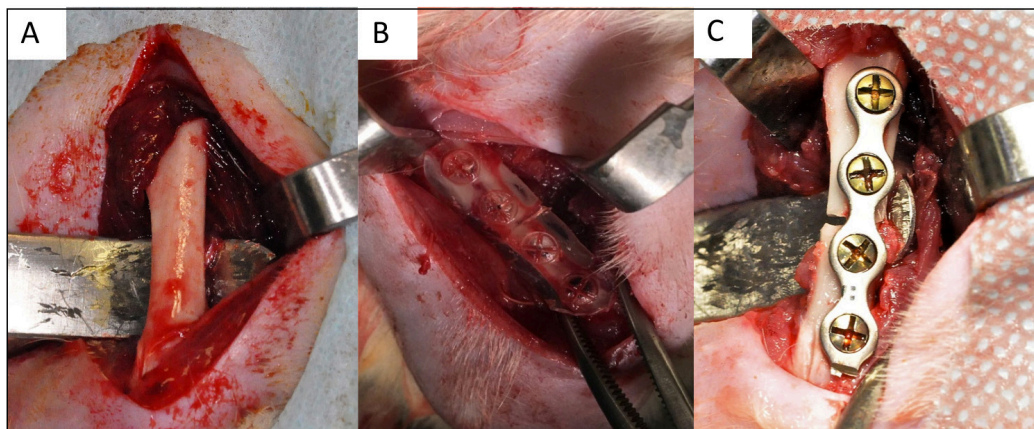
This study was approved by the local Ethics Committee on the Use of Animals (ECUA 391). The experiments were carried out in the vivarium and in the research laboratory and followed all the Animal Research: Reporting of In Vivo Experiments (ARRIVE) guidelines [11].

A total of 10 male Wistar rats (*Rattus norvegicus*), with 4 to 5 months old, weighing 350 to 450 grams, was used in this study, divided in two groups, according to the femoral fracture fixation: titanium plate (TG) and absorbable plates (AG). Throughout the experiment, the ambient conditions of light, temperature and humidity of the rooms were controlled in a digital panel in order to maintain the photoperiod of 12 hours, with the temperature ranging from 18 to 22°C and relative humidity of 65%. For the surgical procedure, the rats were sedated for 1 minute via inhalation with isoflurane 3% (Cristália, Itapira, SP, Brazil), and anesthetized with ketamine hydrochloride 10% (Vetbrands, Paulínia, SP, Brazil) in a dose of 75 mg/kg, and with xylazine hydrochloride 2% in a dose of 10 mg/kg (Vetbrands, Paulínia, SP, Brazil), via intraperitoneal injection.

After, the rats were positioned in left lateral decubitus position, and a trichotomy of right femur was performed followed by vigorous antisepsis using iodopovidone. A straight incision along the axis of the femur was made, approximately 3-cm long, with a 15-C scalpel blade, and the tissues were dissected into muscular planes until the periosteum, which was incised with a scalpel and unglued with a delicate periosteal elevator, exposing the cortical surface of the femur (figure 1A).

Before the femur fracture was performed, the corresponding plates of each group was adapted and fixated on the bone surface in order to avoid the poor positioning of the bone segments. Then, the fracture was performed using a reciprocating saw (NSK, Shinagawa, Tokyo, Japan) under constant irrigation. The stability of plates and screws were checked, hemostasis was reviewed, and the suture was performed in planes with isolated stitches using Vycril 4-0® (Ethicon, Johnson & Johnson, São José dos Campos, SP, Brazil) for the muscles, and nylon 4-0 (Ethicon, Johnson & Johnson, São José dos Campos, SP, Brazil) for the skin.

In the TG, the fixation was performed with a 4-hole titanium plate and four titanium screws of 2 mm system with 4 mm of length (Orthoface, Curitiba, PR, Brazil) (figure 1B). For fixation in the AG, a 4-hole plate and four screws absorbable of 2 mm system with 4 mm of length (Inion Oy Tampere, Finland) were used. To mold and adapt the absorbable plate, they were submerged in warm water and manually molded (figure 1C).



**Figure 1** - Surgical process: (A) femur exposure; (B) titanium; (C) absorbable fixation

Postoperative antibiotic therapy was performed with 10 mg/kg of intramuscular broad-spectrum antibiotic (Pentabiótico Veterinário, Fontoura-Wyeth, São Bernardo do Campo, SP, Brazil) and enrofloxacin 2,5% every 24 hours for 14 days. To control post-operative inflammation, ketoprofen 5 mg/kg was administered intraperitoneally, every 24 hours, for five days. For analgesia, intramuscular morphine 3 mg/kg was administered in the end of surgery, maintained per three days, every six hours. Paracetamol 200 mg/kg diluted in 400 mL of water through the drinking fountains was also administered, likewise ranitidine 5 mg/kg orally, every 24 hours for three days, for gastric protection.

In the postoperative period, the animals were kept in their own cages and fed daily with heavy ration for appetite control (100 mg/day) and water at will. The surgical wound was cleaned with sterile gauze and iodopovidone 10%, once a day, for five days. In a postoperative period of seven days, the animals were clinically and radiographically evaluated about bone and fixations materials position. The clinical follow-up continued once a week, and in cases of fixation failure or infections the animals were early euthanized. The animals were euthanized with 90 days postoperative. The rats were submitted to inhalation of 3% isoflurane until complete absence of vital signs. Soon, both sides femurs, fractured and non-fractured, were

dissected, all titanium fixation material was removed, and the femurs were clinically evaluated and stored in bottles. The plates and screws were removed in fractured side. The non-fractured femurs were used as CG in the mechanical tests.

On the same day, initially, specimens' dimensions were determined using a digital caliper with 0.01 mm accuracy (799; Starrett, Itu, SP, Brazil). The cross-section area was calculated using the equation 1:

$$CS = hb \quad (1)$$

In which:

h = height;

b = width of the bone.

Flexural strength was calculated using the equation 2:

$$S = 3Fl/2bh^2 \quad (2)$$

In which:

S = the flexural strength (MPa);

F = the failure load (N);

l = the distance between the supports;

b = the width;

h = the height of the specimen (mm).

Then, the femurs were submitted to three-point bending flexural test in a universal testing machine (DL2000, Emic, São José dos Pinhais, PR, Brazil). The femurs were individually positioned in a flexural strength support with a span length of 16 mm. The test was performed at a crosshead speed 1 mm/min until fracture (figure 2).






Figure 2 - Flexural strength test

Data were submitted to the statistical analysis using the Statistical Package for the Social Science (SPSS, version 21.0, SPSS Inc., Chicago, IL, United States of America), with the significance level of 0.05. In order to evaluate the normality distribution of the variables, Shapiro-Wilk test was performed. The groups comparisons about the numerical variables were performed through the Kruskal-Wallis and Mann-Whitney tests.

## Results

The table I shows the cross-section area and the flexural strength for all groups. The cross-section in the AG was higher than CG ( $p < 0.001$ ). The TG did not show differences about cross-section with the AG and CG ( $p = 0.544$ ;  $p = 0.062$ , respectively). With respect of flexural strength, the AG was similar with CG ( $p = 1.00$ ), and the TG showed lower flexural strength when compared with CG ( $p = 0.006$ ) and with AG ( $p = 0.042$ ).

Table I - Cross-section area and flexural strength for all groups\*

	Control group (n = 10) Med (min-max)	Titanium group (n = 5) Med (min-max)	Absorbable group (n = 5) Med (min-max)	p-value
<b>Cross-section (mm<sup>2</sup>)</b>	13.96 (9.65–19.18) <sup>a</sup>	25.50 (19.18–30.14) <sup>ab</sup>	75.14 (65.79–90.67) <sup>b</sup>	<b>&lt; 0.001</b>
<b>Flexural strength (MPa)</b>	110.50 (51.41–294.23) <sup>a</sup>	24.61 (20.88–42.10) <sup>b</sup>	191.76 (37.77–314.24) <sup>a</sup>	<b>0.006</b>

\* Kruskal Wallis test and Mann Whitney, with significance level of 0.05; Med: media; min: minimum; max: maximum

## Discussion

The repair process is classified into primary and secondary fracture healings. The primary healing is characterized by direct bone repair without endochondral ossification and does not usually happen in the natural process of fracture healing. In this process, bone remodeling initially occurs under the stable condition of fracture with fixation and no gap formation, with Haversian canal remodeling and reestablishment of blood vessels. The key of this process is the appropriate stability of the fracture site to maintain biological healing response. In the secondary healing, four overlapping stages occur: the initial inflammatory response, callus formation (soft and hard callus), initial bony union and bone remodeling [15]. In

our study, the increased cross section in the bone healing area demonstrated in the AG suggests that a process of secondary healing occurred in these rats with a big callus formation. The TG did not show significant difference in cross section comparing with CG. Maybe titanium plates promoted more rigid fixation, favoring a primary healing and less callus formation.

However, the AG group showed a higher flexural strength, suggesting that the absorbable plates promoted a better repair than the titanium plates in this animal model. Another point is the fact the complete resorption occurs in approximately one post-operative year [6], what could play a favorable role in the results. It seems controversial that our results demonstrated greater flexural strength when the absorbable material was used, since the

titanium materials is related to promote more rigid fixation [16], but interfragmentary motion seems to be needed to active stimulation of periosteal callus formation. Although large movements are critical to bone healing, small interfragmentary movements are beneficial [4]. Also, probably the larger cross-section in the area of bone healing in AG comparing with TG improved the flexural strength, which was also higher in the AG than in TG.

The aim of internal fracture fixation has always been to restore the functional capacity of the broken bone. The overall stability of the fixation and immobilization of the fracture affects the patterns of skeletogenic stem cell differentiation into chondrocytes or osteoblasts. Metallic implants are commonly used in osteosynthesis due to their appropriate mechanical properties and biocompatibility [7]. Although the titanium plates are well established as a great material to the internal fixation, one of the current issues in any type of fracture osteosynthesis is whether the implant needs to be removed once the damage has been repaired [8]. In this context, some studies have noted problems with titanium fixation that have warranted the removal of the titanium plates or screws after the consolidation of bone segments. Even though the absorbable materials like polymers show better biocompatibility, they are also related with foreign body reactions and no sufficient mechanical load carrying capacity for the use in weight bearing bones [7].

In maxillofacial surgery, there are few studies comparing these two materials. Lim *et al.* [9] compared fixation with absorbable and titanium plates for treatment of mandibular angle and symphysis fractures. Primary healing was obtained in both groups, and there were no differences in complication rates. The rupture of three screws during the postoperative period was observed in the group that received absorbable plates, while no screws or plates broke in the group that received the conventional titanium system. In 2017, a systematic review included clinical trials comparing orthognathic surgery patients fixed with absorbable plates and titanium plates. It could be concluded that there is insufficient evidence to determine whether titanium or absorbable plates are superior for bone fixation after orthognathic surgery, both pain and discomfort in the postoperative period, level of patient satisfaction, plate exposure and infection [1].

Clinical studies about fixation in patients are difficult to perform because it is impossible to standardize the fracture and to control other biases

related to the characteristics of the patients. This lack of evidence in comparing these materials for fixation motivated the accomplishment of this pilot study. In this study, there were some difficulties to perform and to adapt the absorbable fixation. The absorbable plates and screws are disadvantageous in size, being larger than the conventional titanium system and the femur diameter. Also, we noted that this animal model was a limitation of this study, and it was impossible to immobilize the animals, occurring excessive movement right after the surgeries. However, another possibility that must be considered is the replication of this study in rabbits, for a better material adaptation.

## Conclusion

The group fixed with absorbable plates demonstrated increased cross-section area compared to the CG and increased flexural strength compared to the group fixed with titanium plates.

## References

1. Agnihotry A, Fedorowicz Z, Nasser M, Gill KS. Resorbable versus titanium plates for orthognathic surgery. *Cochrane Database Syst Rev.* 2017;10(10):CD006204.
2. Atali O, Gocmen G, Aktop S, Ak E, Basa S, Cetinel S. Bone healing after biodegradable mini-plate fixation. *Acta Cir Bras.* 2016;31(6):364-70.
3. Cheung LK, Chow LK, Chiu WK. A randomized controlled trial of resorbable versus titanium fixation for orthognathic surgery. *Oral Surg Oral Med Oral Pathol Oral Radiol Endod.* 2004;98(4):386-97.
4. Claes L, Eckert-Hübner K, Augat P. The effect of mechanical stability on local vascularization and tissue differentiation in callus healing. *J Orthop Res.* 2002;20(5):1099-105.
5. Einhorn TA, Gerstenfeld LC. Fracture healing: mechanisms and interventions. *Nat Rev Rheumatol.* 2015;11(1):45-54.
6. Eppley BL, Sadove AM. A comparison of resorbable and metallic fixation in healing of calvarial bone grafts. *Plast Reconstr Surg.* 1995;96(2):316-22.
7. Hampp C, Angrisani N, Reifenrath J, Bormann D, Seitz JM, Meyer-Lindenberg A. Evaluation of the biocompatibility of two magnesium alloys as degradable implant materials in comparison to titanium as non-resorbable material in the rabbit. *Mater Sci Eng C Mater Biol Appl.* 2013;33(1):317-26.

8. Iglesias C, Bodelón OG, Montoya R, Clemente C, Garcia-Alonso MC, Rubio JC et al. Fracture bone healing and biodegradation of AZ31 implant in rats. *Biomed Mater.* 2015;10(2):025008.
9. Lim HY, Jung CH, Kim SY, Cho JY, Ryu JY, Kim HM. Comparison of resorbable plates and titanium plates for fixation stability of combined mandibular symphysis and angle fractures. *J Korean Assoc Oral Maxillofac Surg.* 2014;40(6):285-90.
10. Marsell R, Einhorn TA. The biology of fracture healing. *Injury.* 2011;42(6):551-5.
11. NC3Rs. Animal Research: Reporting of In Vivo Experiments. Available from: URL: <https://www.nc3rs.org.uk/arrive-guidelines>
12. Neagu TP, Țigliș M, Popp CG, Jecan CR. Histological assessment of fracture healing after reduction of the rat femur using two different osteosynthesis methods. *Rom J Morphol Embryol.* 2016;57(3):1051-6.
13. Shikinami Y, Matsusue Y, Nakamura T. The complete process of bioresorption and bone replacement using devices made of forged composites of raw hydroxyapatite particles/poly l-lactide (F-u-HA/PLLA). *Biomaterials.* 2005;26(27):5542-51.
14. Weiss SG, Kuchar GO, Gerber JT, Tiboni F, Storrer CLM, Casagrande TC et al. Dose of alendronate directly increases trabeculae expansivity without altering bone volume in rat femurs. *World J Orthop.* 2018;9(10):190-7.
15. Yamagiwa H, Endo N. Bone fracture and the healing mechanisms. Histological aspect of fracture healing. Primary and secondary healing. *Clin Calcium.* 2009;19(5):627-33.
16. Zieliński R, Kozakiewicz M, Świniarski J. Comparison of titanium and bioresorbable plates in "A" shape plate properties-finite element analysis. *Materials (Basel).* 2019;12(7):1110.