

Case Report Article
Artigo de Caso Clínico

Complex odontoma associated to a primary maxillary canine: case report

Odontoma complexo associado ao canino decíduo superior: relato de caso

Estela Maris LOSSO*
Eduardo PIZZATTO**
Lucienne Miranda ULBRICH***

Address for correspondence:
Endereço para correspondência:

Estela Maris Losso
Universidade Positivo – Mestrado Profissional em Odontologia Clínica
Rua Professor Pedro Viriato Parigot de Souza, 5.300 – Campo Comprido
CEP 81280-330 – Curitiba – PR
E-mail: emlosso@up.edu.br

* PhD, Professor of Pediatric Dentistry – Positivo University (UP-PR).
** PhD, Professor of Collective Health – Positivo University (UP-PR).
*** MSc, Professor of Dental Surgery – Positivo University (UP-PR).

Received on October 1st, 2008. Accepted on November 3, 2008.
Recebido em 1.º/10/08. Aceito em 3/11/08.

Keywords:

odontoma; impacted tooth; child.

Abstract

Introduction: Odontomas are malformations of the dental tissues and may interfere with the eruption of the associated tooth. The early diagnosis, followed by a proper treatment at the right time, will result in a favorable prognosis and a desirable occlusion development. Complex odontomas associated to primary teeth are rare. **Case report and conclusion:** This article describes a case of a complex odontoma in a four-year-old girl that prevented eruption of the left primary canine. The treatment choice was enucleation of the odontoma and the maintenance of the left primary canine. In this case, complete removal of the complex odontoma was successfully conducted, since after one year of follow-up the primary maxillary canine restarted its eruption process.

Palavras-chave:
odontoma; dente
impactado; criança.

Resumo

Introdução: Odontomas são malformações dos tecidos dentais e podem interferir no processo eruptivo de um dente associado a eles. O diagnóstico precoce, seguido de um tratamento adequado e feito no momento certo, resultará em um prognóstico favorável e em um melhor desenvolvimento da oclusão. Odontomas complexos associados a dentes decíduos são raros. **Relato do caso e conclusão:** Este artigo descreve um caso de odontoma complexo em uma criança de 4 anos de idade, o qual impediu a erupção do canino decíduo superior esquerdo. O tratamento deu-se pela remoção cirúrgica do odontoma complexo e pela manutenção do referido dente. Nesse caso a completa remoção do odontoma foi considerada um sucesso, uma vez que após um ano de acompanhamento o canino decíduo superior esquerdo irrompeu na cavidade bucal.

Introduction

An odontoma is a benign tumor of mixed tissue origin that is located within the facial bones. It consists of masses of enamel, dentin, cementum and pulpal tissues. Radiographically, the lesion presents a well-circumscribed radiolucent image and generally shows a radiopaque border at its periphery. Compound odontomas have a similarity to normal teeth, while complex odontomas are irregular masses. Both odontomas occur predominantly in the second decade of life [5].

The treatment choice for compound odontomas associated to the primary dentition is described in the literature as the surgical removal of the lesion and the maintenance of the arch space until the eruption of the deciduous tooth. This process is estimated to take from 3 months to 2 years. Afterward, the patients could be submitted to the surgical exposure of the deciduous tooth and orthodontic treatment, when needed [2, 7, 8].

There are only a few case reports of complex odontomas associated to the primary dentition in children below five years old [4, 8]. However, there is no case report of spontaneous eruption of the primary tooth after the surgical removal of the complex odontoma.

Case report

A four-year-old white girl was referred to the pediatric dentist's office due to the delayed eruption of the maxillary left primary canine. Extra-oral examination showed no asymmetry. Intra-oral examination revealed normal colored mucosa, increased in volume of the alveolar ridge and absence of the canine (figure 1A). No other abnormalities were found in this examination. The radiograph exam exhibited an irregular radiopaque mass at the incisal border of the canine (figure 1B),

thus preventing its eruption process. The other teeth were present and showed normal development. Based on the clinical and radiographic evaluation, the diagnosis of a complex odontoma associated with this tooth was established.

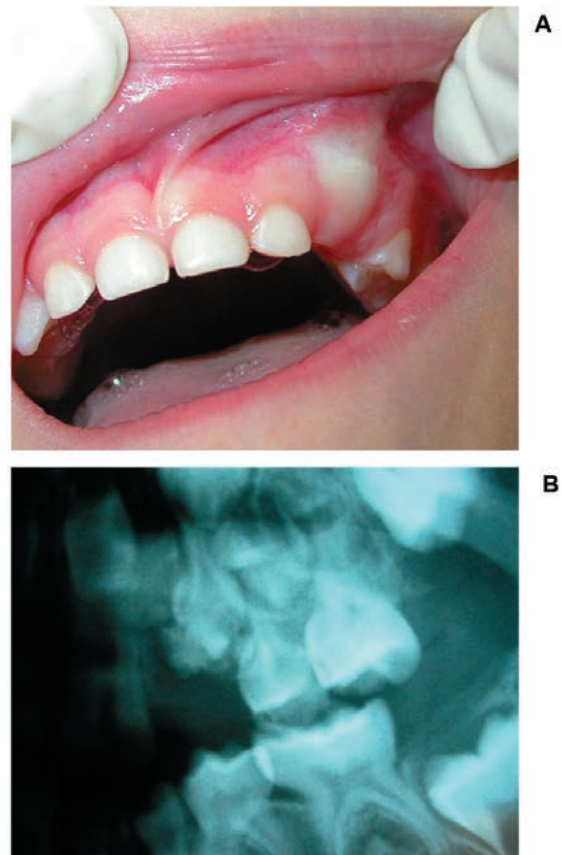


Figure 1 — Clinical evaluation before surgery: (1A) Absence of right primary canine with volume increase of the alveolar ridge; (1B) Radiographic exam showing an irregular radiopaque mass associated to the incisal border of the right primary canine

The patient underwent enucleation of the lesion under general anesthesia (figure 2A and 2B). Since the impacted primary canine was clearly separated from the capsule of the lesion, after the entire lesion had been removed it was decided to keep the primary canine in place and wait its eruption (figure 2C and 2D). During the enucleation of the odontoma, the mobility of the canine revealed no ankylosis of this tooth.

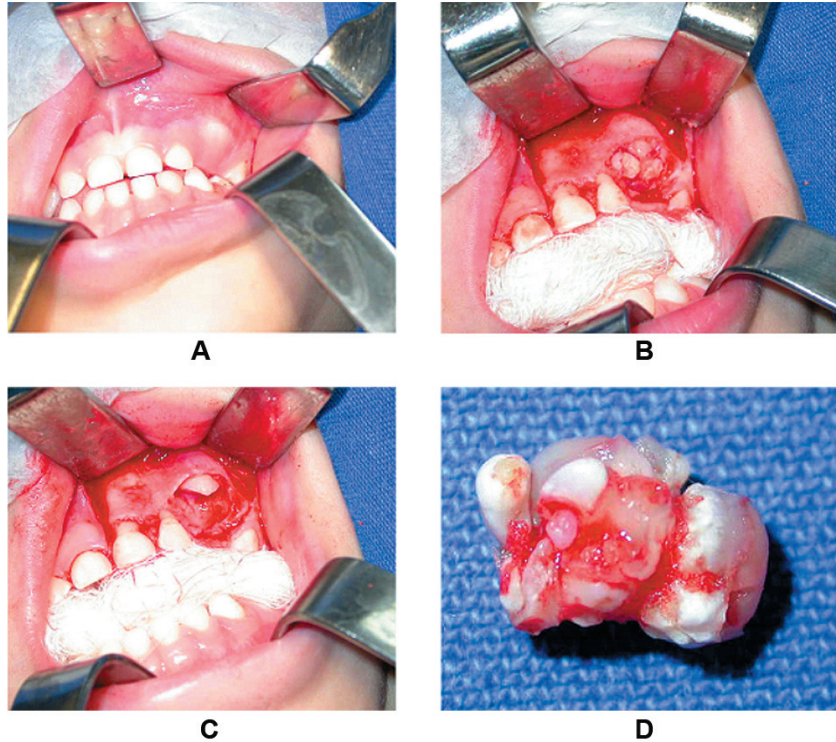


Figure 2 — Surgical procedure: (2A) View of left canine primary region; (2B) View of the complex odontoma before its removal; (2C) View of surgical area after complex odontoma removal; (2D) Surgically removed odontoma macroscopically shows irregular hard tissues

Clinical follow-up was conducted monthly. Four months after surgery, the radiographic examination showed a reduction of the alveolar ridge, although there was no eruption of the canine (figure 3A). After one year of follow-up, the tooth restarted its eruption process (figure 3B and 3C) without any complication.

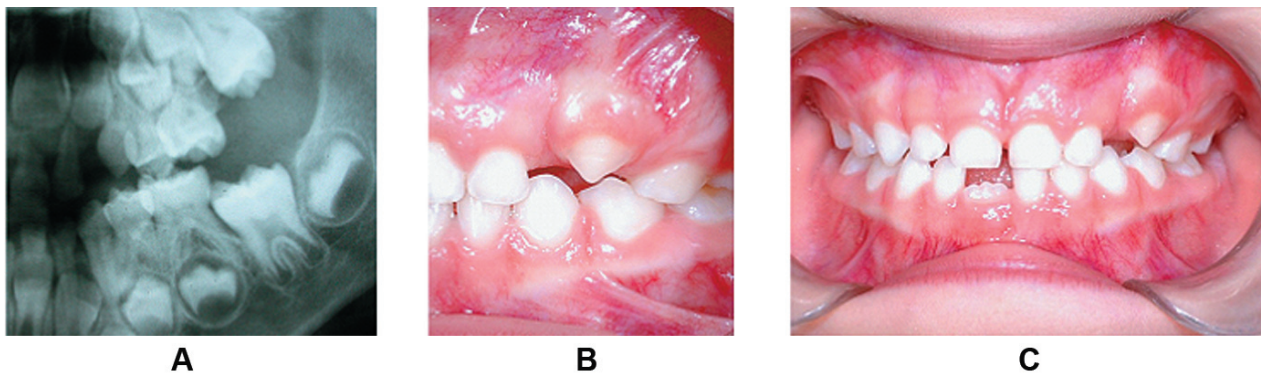


Figure 3 — Clinical follow-up: (3A) 4 months, (3B and 3C) 1 year after the surgery

Discussion and conclusion

A complex odontoma associated to the maxillary left second molar that delayed its eruption process in a three-year-old child was reported by Motokawa et al. [4]. Eight months after the surgical removal of the lesion, surgical exposure of the tooth and orthodontic treatment were administered.

Since the canine of this case report was not inside the odontoma, special care was taken while performing minimum osteotomy in order to remove the lesion and keep enough amount of bone to allow the eruption process of the retained tooth. The child had Baume's arch type I and had no loss of space.

Other authors described spontaneous eruption of primary teeth associated to compound odontomas after the enucleation of the lesion [1, 3, 6, 9]. The time ranged from 3 weeks to 2 years. There was no description of spontaneous eruption of primary teeth associated to complex odontoma in the literature reviewed.

Early diagnosis of odontomas is important for preventing craniofacial and tooth developmental problems. The early diagnosis accompanied by a proper treatment at the right time will result in a favorable prognosis. In order to diagnose developmental abnormalities as soon as possible, a professional team of pediatric dentists should be aware of the importance of clinical and radiographic examinations.

In the present case, there was no need for a second surgery or an orthodontic intervention, so the clinician could preserve the deciduous tooth, avoiding the use of dental appliance as well as aesthetic and emotional problems due to the early loss of deciduous tooth. Thus, this appears to be a suitable treatment strategy for complex odontomas in primary dentition.

References

1. Bacetti T. Interceptive approach to tooth eruption abnormalities: 10-year follow-up of a case. *J Clin Pediatr Dent.* 1995;19(4):297-300.
2. Chen YK, Lin LM, Huang HC, Lin CC, Yan YH. A retrospective study of oral and maxillofacial biopsy lesions in a pediatric population from southern Taiwan. *Pediatric Dent.* 1998;20(7):404-10.
3. Levine N, Stoneman DW. Compound odontoma associated with a primary dentition. *Ont Dent.* 1977;54(5):12-4.
4. Motokawa W, Breaham RL, Morris ME, Tanaka M. Surgical exposure and orthodontic alignment of an unerupted primary maxillary second molar impacted by an odontoma and a dentigerous cyst: a case report. *Quintessence Int.* 1990;21(2):159-62.
5. Neville BW, Damm DD, Allen CM, Bouquot JE. *Oral & maxillofacial pathology.* 2^a ed. Rio de Janeiro: Guanabara Koogan; 2004. 605 p.
6. Noonan RG. A compound odontoma associated with a deciduous tooth. *J Oral Surg.* 1971;32(5):740-2.
7. Sato M, Tanaka N, Sato T, Amagasa T. Oral and maxillofacial tumours in children: a review. *Br J Oral Maxillofacial Surg.* 1997;35(2):92-5.
8. Sheehy EC, Odeel EW, Al-Jaddir G. Odontomas in primary dentition: literature review and case report. *J Dent Child.* 2004;71(1):73-6.
9. Yassim OM. Delayed eruption of maxillary primary cuspid associated with compound odontoma. *J Clin*