

Case Report Article

Fibrous dysplasia of the maxillary sinus: case report

Vijayalakshmi Subramaniam¹
Adarsha Tuluvinakoppa Vasudeva Herle¹

Address for correspondence:

Vijayalakshmi Subramaniam
Dept. of Otorhinolaryngology, Yenepoya Medical College,
Yenepoya University Campus, Deralakatte – Mangalore – 575018
Karnataka – India
E-mail: vijisubbu@gmail.com
Tel.: 91 98862-73009

¹ Department of Otorhinolaryngology, Yenepoya Medical College, Yenepoya University – Deralakatte – Mangalore – India.

Received on April 13, 2010. Accepted on June 16, 2010.

Keywords: fibrous dysplasia; maxillary sinus; Caldwell-Luc approach.

Abstract

Introduction and objective: Fibrous dysplasia is a non-neoplastic lesion of unknown origin with one-fourth involving head and neck. The aim of this paper is to report a case of fibrous dysplasia of the maxillary sinus, describing its clinical presentation, radiological features, histopathological appearance and surgical management. **Case report:** 38-year-old female patient who presented with a history of fullness of the right cheek and intraoral swelling was diagnosed to have fibrous dysplasia of the maxilla with involvement of the maxillary sinus based on the radiological features. The case was managed surgically via a conventional Caldwell-Luc approach. The histopathology of the excised tissue confirmed the diagnosis of fibrous dysplasia. **Conclusion:** Fibrous dysplasia is a benign non-neoplastic lesion of unknown origin that rarely involves the maxillary sinus. This case report highlights the clinical, radiological and pathological features of fibrous dysplasia and its surgical management. Conventional Caldwell-Luc approach allows more exposure and ensures complete removal of the lesion.

Introduction

Fibrous dysplasia is a non-neoplastic lesion of unknown origin with one-fourth involving head and neck. The craniofacial involvement is difficult to treat due to the location of the lesion. Surgery is the treatment of choice in case of complications or for cosmetic reasons.

Case report

A 38-year-old female patient reported with complaints of fullness of the right cheek and swelling in the oral cavity of 4 months' duration. The swelling was insidious in onset and gradually progressive. There were no nasal or other ENT symptoms. Besides, there was no history of loosening of teeth.

The examination showed that there was fullness of the right maxillary region and an intraoral swelling involving the right half of the palate and the alveolar margin (figure 1). The swelling measured about 3x4 cm, extending from 2 cm behind the incisor tooth anteriorly up to the retromolar trigone posteriorly. It extended from the midline medially to the gingivobuccal sulcus laterally. The swelling was tender on palpation and firm in consistency.

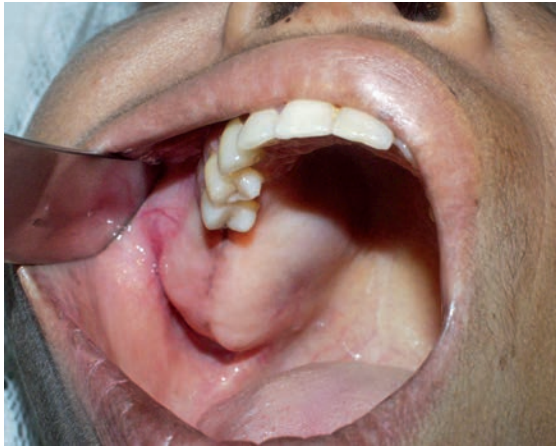

Figure 1 - Clinical photograph of patient showing intraoral swelling involving the right half of the palate and the alveolar margin

The systemic examination was clinically normal, and routine blood and urine examinations were within normal limits. X-ray showed heterogeneous opacity in the right maxillary sinus (figure 2). CT scan demonstrated ground glass appearance over the right maxilla.

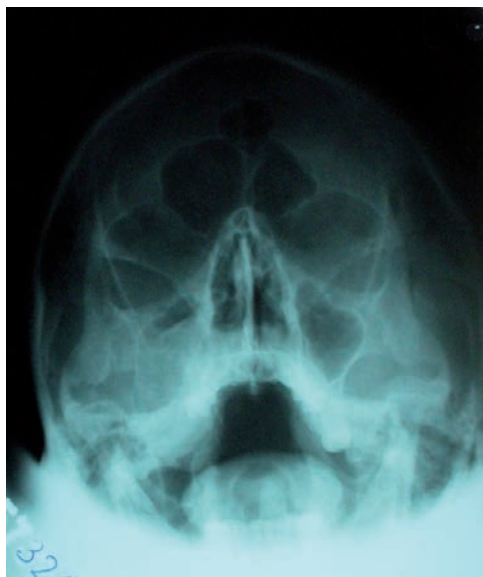

Figure 2 - X-ray PNS (Water's view) showing heterogeneous opacity in the right maxillary sinus

The lesion was excised via a Caldwell-Luc approach (figure 3). The mass involved the anterior, inferior and lateral wall of the maxilla. It was firm in consistency with gritty sensation. Antral pack was removed on the second post-operative day. Progress after surgery was on expected lines and recovery was complete by the time of discharge on the fifth post-operative day.

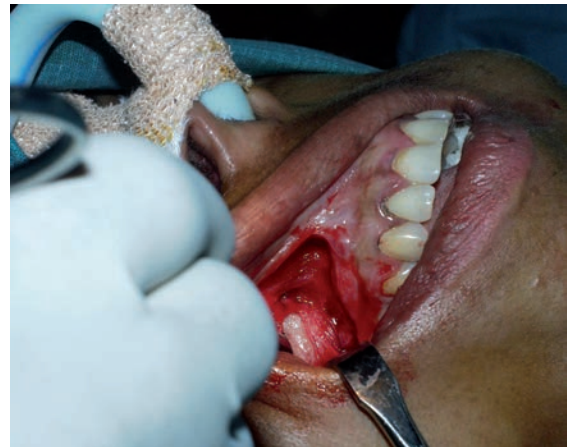

Figure 3 - Excision of lesion via a Caldwell-Luc approach

Histopathology of excised tissue showed a benign fibro-osseous lesion formed by a hypercellular fibroblastic stroma consisting of spindle cells arranged in whorls with storiform pattern and also in loose sheets with intervening collagen interspersed amongst these was immature woven bone with Chinese letter configuration. These features were consistent with fibrous dysplasia (figure 4).

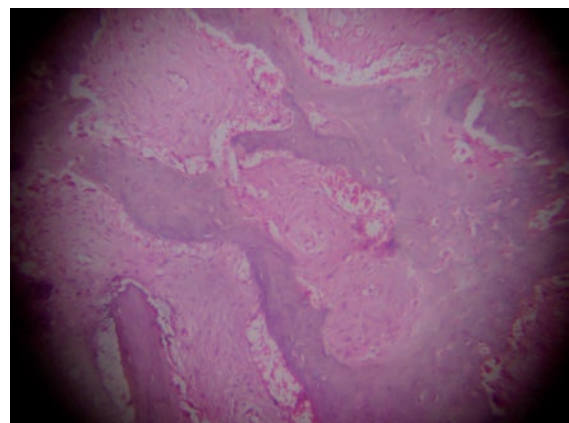


Figure 4 - Histopathology of excised tissue showing features consistent with fibrous dysplasia (H&Ex10X)

Discussion

Fibrous dysplasia is a non-neoplastic expansile lesion of unknown origin. The term fibrous dysplasia

was first introduced by Lichtenstein in 1936 replacing no less than 33 different names used by various authors to describe this disease [2].

It affects the bones of the cranium and face in 3 ways:

1. As a monostotic lesion
2. As one or more lesions of polyostotic disease
3. As one or more lesions of Albright – McCune's syndrome, in which the polyostotic lesions are disseminated and associated with extra-skeletal manifestations such as skin pigmentation and various endocrine manifestations.

The nature and etiology of fibrous dysplasia is obscure and its lesions tend to become inactive or stabilized as skeletal maturity is reached. Moreover, this disease is more common in females.

Monostotic fibrous dysplasia is more common than the polyostotic variety. It occurs in 70-80% of all cases of fibrous dysplasia. Although the maxilla and mandible are most commonly involved, maxillary sinus involvement is rare. Even though conventional radiology has a role, CT scan is the imaging modality of choice.

CT scan will demonstrate classic heterogeneous ground glass appearance with calcifications. Areas of low enhancement and cyst formation can be seen, which aids in differentiating the lesion from malignancy. Though most cases are managed surgically, endoscopic transnasal approaches have been proposed recently [1]. The combination of Pamidronate with limited surgery could be a future possibility for effective therapeutic outcome [3].

The patient reported in this case was 38 years old with a lesion that was reported to be slowly progressive, which is unlike the natural history of

the disease, where the growth corresponds to the period of skeletal growth. Besides, the involvement of the maxillary sinus is very rare. CT scan showed the characteristic appearances as described in literature. Though modern endoscopic transnasal approaches have been described, the conventional Caldwell-Luc approach allows more exposure, thus ensuring complete removal.

Conclusion

Fibrous dysplasia is a benign lesion, which rarely affects the head and neck region. Moreover, the involvement of the paranasal sinuses is rare. CT scan is the investigation of choice. Conventional surgical approach gives better access for complete removal of the lesion.

References

1. Berlucchi M, Salsi D, Farina D, Nicolai P. Endoscopic surgery for fibrous dysplasia of the sinonasal tract in pediatric patients. *Int J Pediatr Otorhinolaryngol.* 2005 Jan;69(1):43-8.
2. Friedman I. Pathology of the cochlea. In: Mackay IS, Bull TR (eds.). *Scott-Brown's Otolaryngology.* London: Butterworth-Heinemann Oxford; 1997.
3. Kos M, Luczak K, Godzinski J, Klempous J. Treatment of monostotic fibrous dysplasia with pamidronate. *J Craniomaxillofac Surg.* 2004 Feb;32(1):10-5.

Como citar este artigo:

Subramaniam V, Herle ATV. Fibrous dysplasia of the maxillary sinus: case report. *Rev Sul-Bras Odontol.* 2010 Jul-Sep;7(3):366-8.
