

## Case Report Article

# Internal root resorption in the maxillary central incisor

Josué MARTOS\*  
Luiz Fernando Machado SILVEIRA\*\*  
Jaqueline de Moraes SOUZA\*\*\*  
Mozara Mignoni VIEIRA\*\*\*  
Carina Folgearini SILVEIRA\*\*\*

### Address for correspondence:

Josué Martos  
Faculdade de Odontologia – Universidade Federal de Pelotas  
Rua Gonçalves Chaves, 457  
CEP 96015-560 – Pelotas – RS  
E-mail: josue.sul@terra.com.br

\* Assistant Professor of FO-UFPEL (School of Dentistry, Federal University of Pelotas). PhD in Dentistry, Universidad de Granada, Spain.

\*\* Assistant Professor of FO-UFPEL. PhD in Dentistry, Universidad de Granada, Spain.

\*\*\* Students of Dentistry at FO-UFPEL.

*Received on September 29, 2009. Accepted on October 20, 2009.*

**Keywords:** dental pulp diseases; root resorption; diagnosis.

## Abstract

**Introduction:** Internal root resorption is a chronic inflammatory process initiated within the pulp space with the loss of dentin. The clastic cells present in the pulp tissue trigger a progressive resorption phenomenon. **Case report and conclusion:** This paper reports a clinical case of an internal root resorption in the permanent central incisor, at the middle third of the root canal. Because it is asymptomatic, internal root resorption needs an early diagnosis in order to institute the endodontic treatment before the process compromises the mineralized structures of the tooth.

## Introduction

Internal resorption is considered to be an inflammatory process established by the association between a pulp aggression, which causes a focal necrosis of the odontoblasts, and a chronic inflammatory process without pulp necrosis [3, 7]. Internal resorptions happen in the surface of the

dentin walls that form the pulp cavity and are not as frequent as the external ones.

In the transitory inflammatory resorption, there are odontoblasts compromising the predentin. When the resorption begins the pulp is alive, however altered by a chronic dental pulp inflammation of long duration. The discontinuity of the odontoblastic layer and the compromise of the predentin expose the dentin and install an autoimmune reaction,

maintained by a chronic pulp inflammation [3]. Thus, the survival conditions become more and more difficult and the pulp necrosis begins starting from its coronal third [8].

The microorganisms can be present since the beginning of the inflammatory process or accessing the pulp when the necrosis begins; in this way they would be responsible for the progression of the destructive process [3]. When the pulp is totally necrotic, the resorption stops. Wedenberg and Lindskog [10] observed that when the necrosis is present usually the communication of the pulp cavity exists with the periodontium in the resorption area. Internal resorptions can be located at the level of the crown or in different thirds of the root.

When the resorption is internal, the image shows an increase of the root canal, in a way that the lines which demarcate the walls of the canal disappear. The image that identifies the external resorptions presents an area of bone rarefaction associated to the dental alteration, while the internal one is confined to the tooth, except when it is communicating. That differential diagnosis is important with respect to the clinical conduct [2, 5].

Another factor to be considered in the differential diagnosis is the use of periapical radiographs in two different incidences. The internal deformity accompanies the image in all of the angulations and the resorption expresses will tend to stand back from the canal when we change the incidence. The treatment of the internal resorptions is the removal of the pulp tissue that shelters the responsible cells for the process [4, 6, 8]. The difficulty is cleaning and filling the deformed area due to resorption [1, 3, 9].

The aim of this work is to report a clinical case of internal resorption in the permanent maxillary central incisor, at the middle third of the root canal.

## Case report

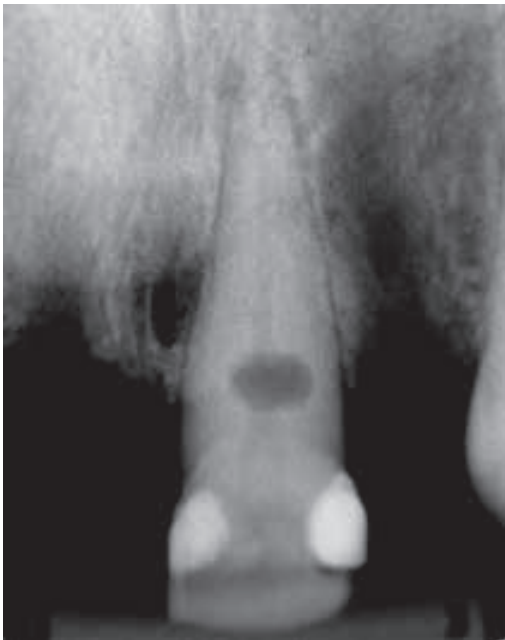A 29-year-old male patient was referred to the Department of Clinics of a School of Dentistry reporting need for dental treatment. The patient required prosthetics rehabilitation due to the lack of several elements. The patient reported no history of dental trauma or discomfort in the maxillary left central incisor and no treatment until that moment. The radiographic examination revealed a well-defined radiolucent area suggesting an internal root resorption at the middle third of the root canal (figure 1). The intraoral examination revealed a

composite resin restoration in this referred teeth at proximal aspect, and the periodontal tissues presented a fistula after probing. Radiographic tracing of the intraoral fistula revealed a lateral lesion (figure 2). Thermal sensitivity testing indicated no pulp vitality.

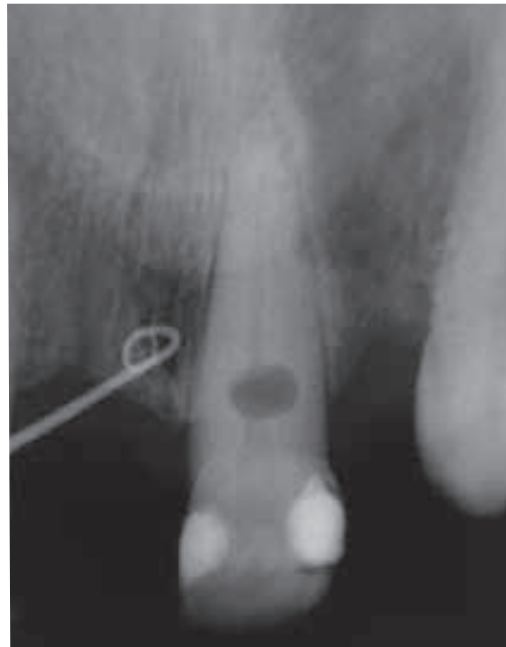
The patient was sufficiently informed about the status of his oral health, as well as the proposed treatment, and signed a consent form, considering the ethical and legal principles to clinical care. The pattern of the dental resorption suggested that an endodontic treatment associated with warm gutta-percha technique would be a reliable option for the case. After rubber dam isolation (Dental Dam, Coltène/Whaledent, Switzerland) of the central incisor, the biomechanical preparation was accomplished to enlarge the root canal in the cervical segment up to the resorption area in order to allow an adequate cleaning of the referred area (figure 3). A sodium hypochlorite solution highly concentrated (2.5%) was used with the purpose of dissolving the necrotic tissues of the concavities in the resorption area.

Because of the identification of pulp necrosis, as pointed out by Wedenberg and Lindskog [10], there would be the possibility of the resorption to be communicating. Therefore, we opted for the temporary dressing of intracanal medication with calcium hydroxide (Merck, Rio de Janeiro), for the period of 30 days, with change of the medication after 15 days (figure 4). The crown was sealed with intermediate restorative material (IRM, Caulk/Dentsply, Rio de Janeiro). The purpose was to make possible a better cleaning of the resorption area in order to allow a repair at the level of the probable communication.

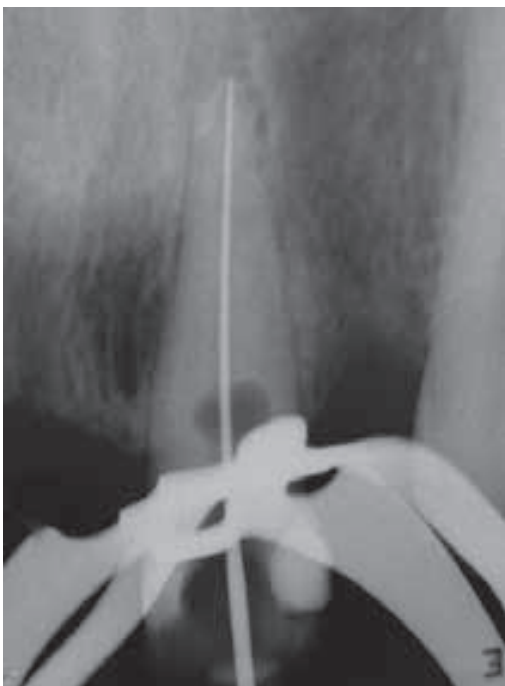
After that period, the root canal filling combining lateral condensation and thermo-mechanical compaction of gutta-percha with the use of McSpadden compactors (Dentsply/Maillefer, Ballaigues, Switzerland) and a calcium hydroxide-based sealer (Sealapex, SybronEndo, USA) was performed. The cavity of endodontic access was sealed with glass ionomer cement (Vitremmer, 3M Dental Products, St. Paul, USA) and photopolymerized composite resin (Z100, 3M Dental Products, St. Paul, USA). Radiographic image taken after the root canal filling demonstrated the sealing of the intracanal resorption. A twelve-month postoperative radiograph showed a clinically significant healing of the previously resorption area (figure 5) and the healing of the periodontal fistula.



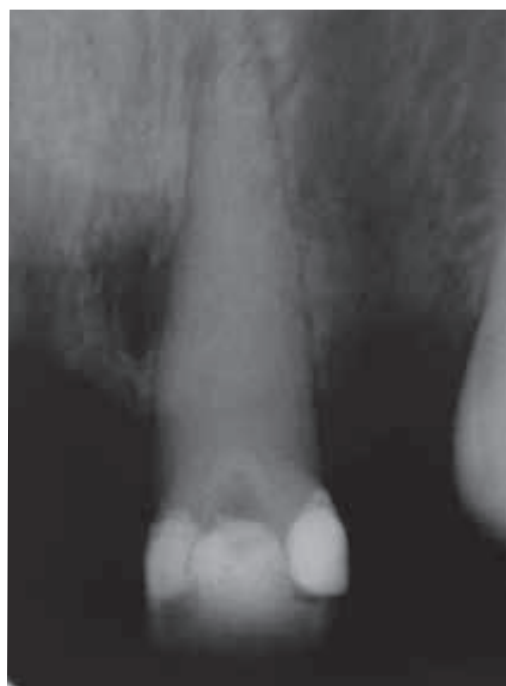**Figure 1** - Initial X-ray showing a radiolucent area indicating internal root resorption at the middle third of the root canal



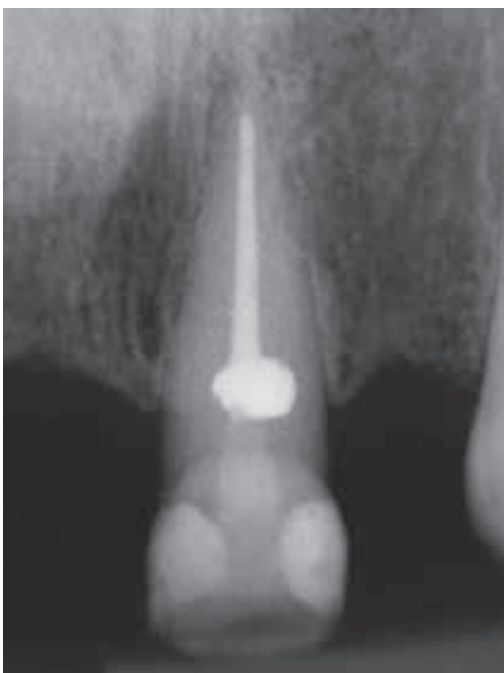**Figure 2** - Radiographic tracing of the intraoral fistula



**Figure 3** - Radiographic interpretation for assessment of the root canal length



**Figure 4** - The root canal was filled with intracanal medication using a calcium hydroxide-based sealer



**Figure 5** - Radiographic image of the root canal filling showing the root resorption sealed

## Discussion

The endodontic treatment of teeth with internal root resorption is complicated due to the difficulty in removing the tissue of the resorption cavity. The remainders of tissue can prevent the cicatrization if communication with the periodontium exists. However, the soft tissue can be dissolved by the use of sodium hypochlorite in high concentrations followed by the application of intracanal medication with calcium hydroxide. In case of small communication, the calcium hydroxide is maintained by a long period for the apposition of hard tissue sealing the communication with the periodontium [1].

Internal root resorption can be associated to several conditions such as occlusal trauma, abfraction, bruxism and many others. However, the word idiopathic is used when the cause/effects relationship cannot be identified, in other words, the cause was in an imperceptible threshold that the patient doesn't tell in the anamnesis. Nevertheless, the etiology doesn't influence on the institution of the endodontic protocol treatment for those cases, but it would allow the prevention in the emergence of other cases in the same patient [3, 7].

The difficulty in cleaning the concavity resorption area requests a cleaning with chemical

substances that have an appropriate organic solvent capacity [11]. The endodontic instrumentation of that resorption area can cause a communication with the periodontium that could complicate the prognostic. Complementing the action of the sodium hypochlorite, we used the intracanal medication with calcium hydroxide for a prolonged period [3, 9]. The use of a calcium hydroxide-based sealer would allow the alkalinity maintenance, preventing a resorption recurrence. Thus, the protocol of endodontic treatment was constituted in cases of internal root resorption based on the pertinent literature [5, 9].

When determining a prognostic for a tooth with internal root resorption, endodontically treated, the need for radiographic control every six months for at least two years should be considered. Such fact is due to the possibility of the area involved by the resorption to present a lateral canal, which would allow the continuity of the resorption process and compromise the treatment [3].

## Conclusion

The clinical case demonstrates that the endodontic treatment instituted in agreement with the suitable protocol in the pertinent literature allows the clinical resolution of internal root resorption.

## References

1. Andreasen JO, Andreasen FM. Textbook and color atlas of traumatic injuries to the teeth. 3 ed. Copenhagen: Munksgaard; 1994. p. 13-735.
2. Çaliskan MK, Türkün M. Prognosis of permanent teeth with internal resorption: a clinical review. *Endod Dent Traumatol.* 1997 Apr;13(2):75-81.
3. Consolaro A, Consolaro RB, Prado RF. Reabsorção interna: uma pulpopatia inflamatória. Maringá: Dental Press; 2005. p. 572-94.
4. Culbreath TE, Davis GM, West NM, Jackson A. Treating internal resorption using a syringeable composite resin. *J Am Dent Assoc.* 2000 Apr;131(4):493-5.
5. Fachin EVF, Salles AA, Fachin GF. Reaction of the pulp tissue: co-occurrence of pulp stone and internal resorption. *Rev Fac Odontol Porto Alegre.* 2007 Jan;48(1):92-4.

6. Jacobovitz M, de Lima RKP. Treatment of inflammatory internal root resorption with mineral trioxide aggregate: a case report. *Int Endod J*. 2008 Oct;41(10):905-12.
7. Nascimento GJF, Emiliano GBG, Silva IHM, Carvalho RA, Galvão HC. Mecanismo, classificação e etiologia das reabsorções dentárias. *Rev Fac Odontol Porto Alegre*. 2006 Dec;47(3):17-22.
8. Silveira CF, Silveira LFM, Martos J. Tratamento endodôntico de incisivos centrais superiores com reabsorção radicular interna – caso clínico. *Rev Endod Pesq Ens On Line*. 2008 Jan;4(7):1-6.
9. Soares IJ, Goldberg F. Endodontia técnica e fundamentos. Porto Alegre: Artmed; 2001. p. 339-68.
10. Wedenberg C, Lindskog S. Experimental internal resorption in monkey teeth. *Endod Dent Traumatol*. 1985 Dec;1(6):221-7.
11. Araújo CJR, Souza VS, Baratto Filho F, Limongi O, Rios MA, Albuquerque DS. Capacidade de dissolução do hipoclorito de sódio em diferentes concentrações. *Rev ABO Nac*. 2006 Aug/Sep;14(4):237-41.

---

**Como citar este artigo:**

Martos J, Silveira LFM, Souza JM, Vieira MM, Silveira CF. Internal root resorption in the maxillary central incisor. *Rev Sul-Bras Odontol*. 2010 Jun;7(2):239-43.

---