

## Case Report Article

# Functional-aesthetic treatment of crown fracture in anterior teeth with severe crowding

Diego Henrique da Silva Mendonça<sup>1</sup>  
Mario Lúcio da Costa Azevedo<sup>1</sup>  
José Carlos Dal Secco Leandrini<sup>1</sup>  
Aline Evangelista Souza-Gabriel<sup>1</sup>

### Corresponding author:

Aline Evangelista Souza-Gabriel  
Av. Costábile Romano, 2.201  
CEP 14096-900 – Ribeirão Preto – SP – Brasil  
E-mail: aline.gabriel@gmail.com

<sup>1</sup> School of Dentistry, University of Ribeirão Preto – Ribeirão Preto – SP – Brazil.

*Received for publication: June 30, 2011. Accepted for publication: February 7, 2012.*

**Keywords:** esthetics;  
tooth preparation;  
incisor; Pediatric  
Dentistry; dental  
restoration permanent.

## Abstract

**Introduction:** Traumatic injuries are usually the result of impacts whose aggressive strength exceeds the resistance found in bone, muscle and tooth tissues. With the advent of the etching technique and considering the improvement of composite resins, simpler and more conservative alternatives are indicated in the aesthetic and functional rehabilitation of fractured anterior teeth. **Case report and objective:** This study aimed to report the treatment of a 13 year-old patient that fractured his central incisor due to a trauma. After clinical and radiographic examination, an oblique crown fracture with extensive involvement of the incisal angle, without pulp exposure or injury to the biological space of the left maxillary central incisor (tooth #21) was observed. Because the fractured tooth fragment was lost, it was not possible to process a fragment bonding. Thus, it was proposed to treat the tooth through direct technique restoration with composite resin. **Conclusion:** It can be concluded that the aesthetic and functional rehabilitation with direct composite resin is a viable option for the conservative treatment of fractured anterior teeth.

## Introduction

Tooth trauma is a frequent emergency situation at dental offices [19]. The high rates of violence, car accidents, and greater participation of children in sports activities have contributed to consider tooth trauma as an increasing public health problem [20].

Tooth trauma lesions comprise from a simple enamel fracture to the total loss of the tooth. Enamel and dentin fractures without pulp exposure do not require an emergency treatment because their prognosis is favorable even for late treatment. Crown fractures with pulp exposure, intrusive luxation, concussion, subluxation and primary tooth trauma are considered injuries of moderate severity and demand an early treatment [15, 19].

There is a predominance of tooth trauma in male subjects, especially at school and growing age, as a consequence of falls, fights, sports or car accidents, trauma due to objects and child abuse [5, 19]. Children showing anterior open bite, marked overjet, inappropriate lip coverage in addition to inappropriate lip sealing are more prone to trauma than children with normal occlusion [4, 5, 10, 20]. Social-economical factors have not been associated to more occurrences of tooth trauma lesions [4].

Both the physical and the psychological damage are present in tooth trauma. The lesions in the anterior teeth may result in unfavorable effects on the function and affect the self-esteem, the behavior and the professional success, especially if there is the loss of the permanent tooth structure [4, 18, 20-22]. Avulsion, root and bone fractures have been considered as the most serious acute situations and should also receive an early treatment [18, 19].

Emergency situations involving the head and neck frequently are dramatic experiences for both the parents and the children. In several times, the early treatment is not performed because of either the lack of knowledge of the parents or by the fact that the emergency care is provided by hospitals, medical offices or public health centers. All these factors together result in the delaying of the dentist's evaluation, affecting the treatment prognosis [4, 19].

This limitation of the knowledge on the proper procedures regarding to tooth traumas, mainly avulsions, reinforces the need of education on not only the initial treatment but also on the preventive measures [4].

The aim of this study was to report the treatment of a 13-year-old male patient who suffered a trauma on the central incisor due to a fall.

## Case report

A male patient was referred to the dentistry clinic of the University of Ribeirão Preto (short Unaerp) to restore a fractured anterior tooth. During the anamnesis, the patient reported that a fall had caused the tooth fracture. The clinical and radiographic examinations revealed that the left maxillary central incisor (tooth #21) showed an extensive oblique crown fracture involving the incisal angle (Class IV), without pulp exposure or involvement of the biological space; also the tooth was crowded and labially rotated (figures 1A, 1B, 1C and 1D).

Additionally the patient reported that the trauma occurred one year ago, and the tooth fragment was lost. Therefore, it was not possible to perform a fragment bonding. The treatment proposed was to restore the tooth through direct composite resin technique.

At the first appointment, alginate impressions (Jeltrate, Dentsply, Petrópolis, RJ, Brazil) were executed to obtain study casts (dental stone, type IV – Durone IV (Dentsply, Petrópolis, RJ, Brazil), which were mounted in semi adjustable articulator to analyze the occlusion, perform the diagnostic waxing, and construct a silicone palatal guide (Perfil, Vigodent, Bonsucesso, RJ, Brazil).

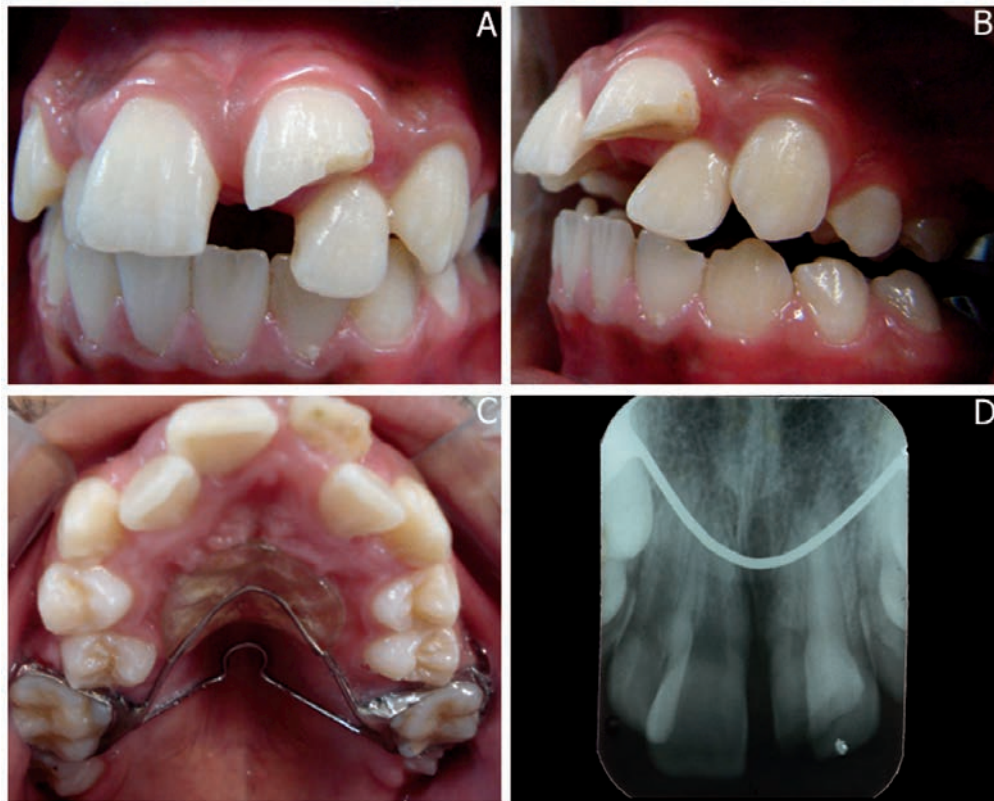At the second appointment, a prophylaxis was performed and tooth color selected through Vitta Classical scale, resulting in the shade A1 for both the enamel and dentin.

The patient was submitted to anesthesia and absolute isolation by adapting a clasp (#212R) because the tooth was crowded and labially rotated (figure 2A).

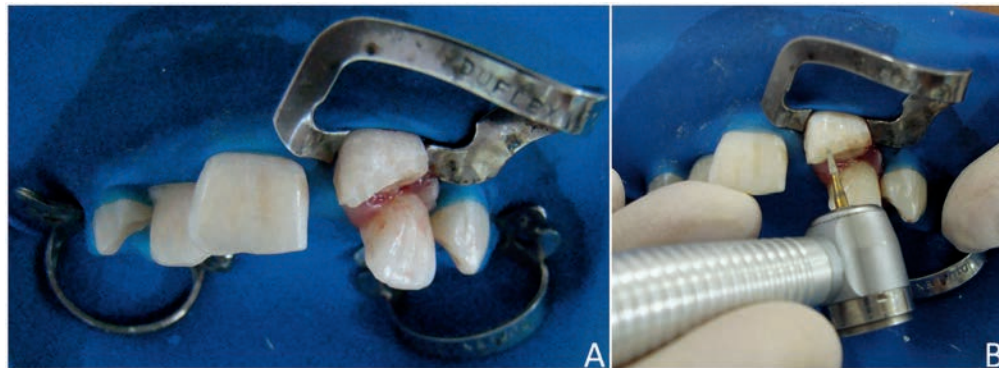
Following, a bevel was constructed with the aid of a #1190F bur (KG Sorensen, Barueri, SP, Brazil) at high speed (figure 2B). The silicone guide was tried on and adapted and the bonding technique protocol was initiated: enamel etching for 30 seconds, washing, drying, application and light-curing of the adhesive system (Adper Single Bond 2, 3M ESPE, Sumaré, SP, Brazil). Then, the silicone guide was positioned on the palatal surface of the tooth and an increment of composite resin was applied (T neutral shade - Opallis, FGM, Joinville, SC, Brazil) to restore the palatal enamel, followed by light-curing for 30 seconds. After the construction of the palatal surface, a second layer of resin (DA1 shade - Opallis, FGM, Joinville, SC, Brazil) was inserted to restore the dentin. At this stage, the anatomical characteristics were reproduced. The last layers of composite resin

(EA1 shade – Opallis, FGM, Joinville, SC, Brazil) were inserted and sculpted with the aid of a brush for composite resin reproducing the texture of the labial surface.

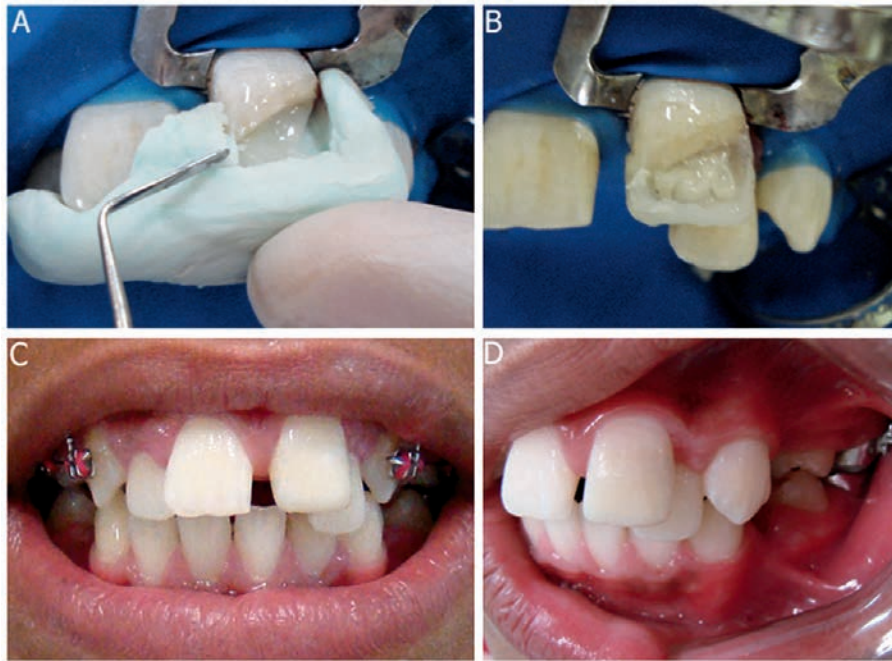
After the removal of the absolute isolation, the restoration finishing was executed, and the occlusion was adjusted through finishing burs. At the following appointment, the restoration polishing was performed through abrasive discs (Sof-Lex Pop-On, 3M ESPE, St. Paul, MN, USA), abrasive rubber points (Enhance, Dentsply, Petrópolis, RJ, Brazil), felt discs with abrasive paste, and silicon carbonate brush (Astrobrush, Ivoclar Vivadent, Amherst, NY, USA). A smooth, bright surface was obtained and an aesthetic, improved, more harmonious outcome was achieved. The treatment met the patient's expectation. After 18 months of following-up, the tooth is asymptomatic and the patient is undergoing orthodontic treatment.



**Figure 1** - A) Frontal view of the occlusion. Tooth #21 showing large oblique crown fracture; B) Left lateral view; C) Maxillary occlusal view; D) Periapical radiograph of the central incisors



**Figure 2** - A) Frontal view of the absolute isolation of the operative field ; B) Bevel preparation through #1190F bur (KG Sorensen) at high speed



**Figure 3** - A) Silicone palatal guide adapted and insertion of composite resin increment; B) Insertion of opaque composite resin increment for construction of the artificial dentin; C) Frontal view - treatment concluded; D) Final aspect of the restoration after repolishing, 6-month following-up

## Discussion

The restorations in fractured anterior teeth are aesthetic-functional solutions for the consequences of a tooth trauma. They are also required by the patients to improve their appearance, providing greater comfort and psychosocial well-being [6, 13]. In the case report presented here, the construction of a direct composite resin restoration was the most viable and efficient treatment choice, mainly because of the good clinical performance of this material, which exhibits an easy handling and large variety of color shades, resulting in an almost imperceptible restoration [13].

The mechanical resistance of fractured teeth is compromised, because they show an irreversible loss of tooth structures. Several direct restorative systems have been employed, displaying different performance in enamel and dentin [9].

The treatment of the fractured central incisor reached results as the maintenance and integrity of the tooth, as well as the recovering of the patient's self-esteem, due to the improvement of tooth aesthetic and consequently of the patient's emotional state.

Tooth trauma is very common during childhood and adolescence. The crown fractures exhibited the highest percentage of all traumatic injuries in permanent dentition (26% to 76%), followed by luxations; the most affected area is the crown of the

teeth, mainly the enamel [16, 22]. In either primary or permanent teeth, the trauma is frequently a severe aesthetic, functional and psychological problem, and, it may be considered as an emergency situation, not only by the tooth problems and their future consequences, but also by the child and parents' emotional involvement [1, 12].

Camargo and Guedes-Pinto reported that in children at 7 to 13 years-old, 59.2% of the 167 tooth fractures found were in enamel and dentin. The most common type of crown fracture line is oblique (69.3% of the cases), followed by horizontal (28.9%) and vertical (1.8%) [12]. In the case presented here, the patient presented a large oblique crown fracture without pulp exposure in tooth #21.

Studies have indicated that the incidence of tooth trauma is higher in males than females, at 2:1 ratio [4, 5, 10, 20, 22]. In the school and teenage age range, the traumas occur because of several accidents, such as falls; strikes; bicycle, car and sports accidents, among others. Also, the child and teenager abuse should be emphasized [12]. Additionally, the highest occurrence of tooth traumas is verified at home, during school vacations, when children are freer and play more [12].

The treatment of the patient presenting tooth trauma basically comprises: controlling of the parents' anxiety, brief history in cases of

emergency care, trauma history, assessment of general symptoms, fast behavior guidance of the child, clinical examination, cleaning of the area, radiographic examination, diagnosis, and treatment planning; all information should be registered in the patient's file [12].

In cases of crown fracture, either the tooth fragment bonding or the tooth restoration through composite resin is the most adequate immediate treatment for this type of trauma. The restoration of a tooth undergoing a trauma and showing a crown fracture involving the enamel and dentin is performed through the restoration by light-cured composite resin employing the enamel etching and adhesive systems [1, 6, 8].

The immediate care of the traumatized teeth and the future of the oral health of the patient demand not only the emergency treatment, but also an appropriate long-term following-up. Because of the multidisciplinary involvement required for the treatment of these cases, the general dentist is the most appropriate professional to perform it [15].

Therefore, the dentist must be prepared to solve the problem from both the therapeutic and emotional standpoint. Consequently, the dentist must have control of the situation, showing knowledge, serenity and security to both the patient and parents. The professional should establish an adequate treatment planning, minimizing further sequelae and providing a higher probability of the traumatized tooth maintenance until the patient reaches the adult age [6, 12, 13].

In the case presented here, the aesthetic-functional treatment of the fractured tooth (#21), employing the direct composite resin technique, obtained a good outcome and reestablished the physical and mainly psychological health of the patient.

## Conclusion

It can be concluded that the aesthetic-functional rehabilitation with direct composite resin is a viable option for the conservative treatment of fractured anterior teeth.

## References

1. Andreasen JO. Essentials of traumatic injuries to the teeth. 1. ed. Copenhagen: Munksgaard; 1991.
2. Avelar FM, Penido CVSR, Cruz RA, Penido SMMO. Colagem homogênea de fragmento dentário em incisivo central superior permanente – relato de caso clínico. *RFO*. 2009;14(1):66-70.
3. Bendo CB, Paiva SM, Torres CS, Oliveira AC, Goursand D, Pordeus IA et al. Association between treated/untreated traumatic dental injuries and impact on quality of life of Brazilian schoolchildren. *Health Qual Life Outcomes*. 2010;8(114):1-8.
4. Bonini GAVC, Marcenes W, Oliveira LB, Sheiham A, Bönecker M. Trends in the prevalence of traumatic dental injuries in Brazilian preschool children. *Dental Traumatol*. 2009;25(6):594-8.
5. Cavalcanti AL, Bezerra PKM, De Alencar CRB, Moura C. Traumatic anterior dental injuries in 7 – to 12 year-old Brazilian children. *Dental Traumatol*. 2009;25(2):198-202.
6. Conceição EN. *Dentística saúde e estética*. 2. ed. Porto Alegre: Artmed; 2007.
7. De Rossi M, De Rossi A, Queiroz AM, Nelson-Filho P. Management of complex dentoalveolar trauma: a case report. *Braz Dent J*. 2009;20(3):259-62.
8. Fidel RAS. Complicated crown fracture: a case report. *Braz Dent J*. 2006;17(1):83-6.
9. Garcia RN, Alvarez AEG, Dias CE, Mazaro MA, Firmo T, Stuker H et al. Avaliação da resistência de união de sistemas restauradores contemporâneos em esmalte e dentina. *RSBO*. 2011;8(1):60-7.
10. Goenka P, Marwah N, Dutta S. Biological approach for management of anterior tooth trauma: triple case report. *J Indian Soc Pedod Prev Dent*. 2010;3(28):223-9.
11. Góes KKH, Ribeiro ED, Lima Júnior JL, Silva Neto JM. Avaliando os traumatismos dentoalveolares: revisão de literatura. *Rev Cir Buco-Maxilo-Facial*. 2005;5(1):21-6.
12. Guedes-Pinto AC, Wanderley MT, Bonini GAVC, Cadioli IC, Prokopovitch I. *Odontopediatria*. 8. ed. São Paulo: Santos; 2010.

13. Melo LL. Traumatismo alvéolo-dentário. 1. ed. Série EAP-APCD, v. 9. São Paulo: Artes Médicas; 1998.
14. Melo REVA, Silva MBL, Vitor CMA, Luna LA, Firmo ACB. Traumatismo dentoalveolar. *Int J Dent.* 2003;2(2):266-72.
15. Oliveira FAM, Gerhardt MO, Orso VA, Oliveira VR. Traumatismo dentoalveolar: revisão de literatura. *Rev Cir Buco-Maxilo-Facial.* 2004;4(1):15-21.
16. Poi WR, Pignatta LMB, Ricieri CB, Panzarini SR, Sonoda CK. Tratamento de urgência em traumatismo dento-alveolar. *RGO.* 2005;53(3):181-5.
17. Rezende FMC, Gaujac C, Rocha AG, Peres MPSM. A prospective study of dentoalveolar trauma at the Hospital das Clínicas, São Paulo University Medical School. *Clin Sci.* 2007;62(2):133-8.
18. Sakai VT, Magalhães AC, Pessan JP, Silva SMB, Machado MAAM. Urgency treatment profile of 0 to 15 year-old children assisted at urgency dental service from Bauru Dental School, University of São Paulo. *J Appl Oral Sci.* 2005;13(1):340-4.
19. Sanabe ME, Cavalcante LB, Coldebella CR, Abreu-e-Lima FCB. Urgências em traumatismos dentários: classificação, características e procedimentos. *Rev Paul Pediatr.* 2009;27(4):447-51.
20. Traebert J, Almeida ICS, Garghetti C, Marcenes W. Prevalência, necessidade de tratamento e fatores predisponentes do traumatismo na dentição permanente de escolares de 11 a 13 anos. *Cad Saúde Pública.* 2004;20(2):403-10.
21. Turkistani J, Hanno A. Recent trends in the management of dentoalveolar traumatic injuries to primary young permanent teeth. *Dental Traumatol.* 2011;27(1):46-54.
22. Vasconcellos RJH, Oliveira DM, Porto GG, Silvestre H, Silva E. Ocorrência de traumatismo dental em escolares de uma escola pública do Recife. *Rev Cir Buco-Maxilo-Facial.* 2003;3(4):9-12.