

## Case report article

# Conservative technique for the removal of implants displaced into maxillary sinus

Andreia Moleta<sup>1</sup>  
Luise Machado Brasil<sup>1</sup>  
Edmar Rafael de Oliveira<sup>2</sup>  
Suyany Gabriely Weiss<sup>1</sup>  
Driele Gontarz<sup>1</sup>  
Renan Dainez de Sant'ana<sup>1</sup>  
Mainara Bassetto Ecker<sup>1</sup>  
Katheleen Miranda dos Santos<sup>1</sup>  
Leandro Eduardo Kluppel<sup>2</sup>  
Tatiana Miranda Deliberador<sup>1</sup>  
Rafaela Scariot<sup>1</sup>

### Corresponding author:

Rafaela Scariot  
Rua Prof. Pedro Viriato Parigot de Souza, n. 5.300 – Campo Comprido  
CEP 81280-330 – Curitiba – Paraná – Brasil  
E-mail: rafaela\_scariot@yahoo.com.br

<sup>1</sup> Department of Dentistry, Positivo University – Curitiba – PR – Brazil.

<sup>2</sup> Department of Dentistry, Federal University of Paraná – Curitiba – PR – Brazil.

*Received for publication: September 12, 2019. Accepted for publication: November 18, 2019.*

### Palavras-chave:

dental implants;  
maxillary sinus;  
displacement; surgery.

## Abstract

**Introduction:** Displaced dental implants into the maxillary sinus are relatively rare. Treatment consists of implant surgical removal. **Objective:** To present two case reports of the removal of implants displaced into maxillary sinus by a conservative technique. **Case report:** Report 1: A 44-year-old female sought for treatment complaining about headaches and recurrent sinusitis. In the anamnesis she reported she had been undergone placement of nine maxillary implants, fifteen years ago, with total loss of those elements. At the imaging exams it was possible to observe two displaced implants into the bilateral maxillary sinus, besides radiopaque image on the left maxillary sinus, compatible with maxillary sinusitis. Based on this data, the proposed treatment plan was the removal of the displaced implants through Caldwell Luc approach and sinusotomy in the left side, under general anesthesia. The patient has a follow-up of 6 months without complaints. Report 2: A 42-year-old male was referred to the Surgery and Maxillofacial Traumatology Department for implant removal from the right maxillary sinus. Patient underwent implant installation in the area around 9 months ago. In the computerized tomography it was possible to diagnose the implant migration into the

right maxillary sinus. the proposed treatment plan was the removal of the displaced implant via Caldwell Luc Access by repositioning the bony window and sinusotomy. **Results:** Patient has been with no complaints at 30 days after surgery. **Conclusion:** The technique has been shown to be effective in treating the condition.

---

## Introduction

Dental implantology has shown to be a therapeutical modality with high predictability levels, provided the basic planning criteria are analyzed. Accidents and complications caused by non-compliance of those criteria while installing dental implants in the maxillary posterior area are likely to lead to unexpected surgical complications, which is the accidental displacement of instruments or implants into the maxillary sinus [1]. Displacement might happen more often in patients who undergo simultaneously implants placement and bony grafting after sinus elevation [14]. Another factor is the height decrease in the residual alveolar bone, in particular the placement of implants on the bone at a minimum height of less than 4 mm with simultaneous bony grafting [4]. Other factors that influence the displacement are lack of primary stability, inexperience of the surgeon, use of temporary prosthesis without relief, over instrumentation and inappropriate strenght application while non-integrated implants removal [10]. Thus, dental implant displacement or migration to the maxillary sinus is an undesirable occurrence [18].

The anamnesis, the physical examination and imaging are indispensable for the Diagnostic, and the computerized tomography are fundamental to define the right position of an odd body [15]. There are several methods to remove the implant from maxillary sinus, such as: aspiration through a bony alveolar fault, Caldwell-Luc technique, functional endoscopic sinus surgery (FESS) and access through transoral endoscopy by canine fosse [18]. Treatment must be determined according to the size and location of the strange body and maxillary sinus conditions [17].

In the conventional Caldwell-Luc access, a big part of the anterior maxillary wall and sinus epithelial tissue is removed. One of the biggest advantages of that technique is the good visualization of the operating area, providing a

better visibility of the injuries, improving access to sinus, avoiding serious complications; therefore, that technique has been the most used surgical procedure for maxillary pathology [7]. Caldwell-Luc technique is effective and indicated to isolated endoscopy procedures or when are associated together with the use that technique [19]. It has been reported between 10 and 40% of immediate to the technique complications like damages to the orbit floor, optic nerve and eyeball. There may also be complications like extravasation of cerebrospinal fluid due to perforation of the plaque cribiform, osteomyelitis and formation of osteoma and mucoceles of the maxillary sinus [7].

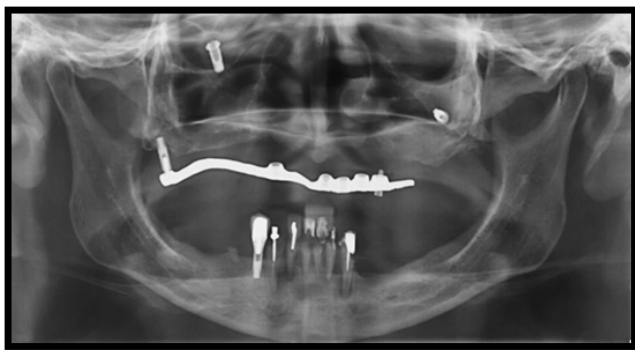
The objective of this study was to report two cases of implants removal displaced into the maxillary sinus through Caldwell-Luc modified technique, followed by the replacement of the anterior wall into maxillary sinus with plaques and titanium screws.

## Case presentation 1

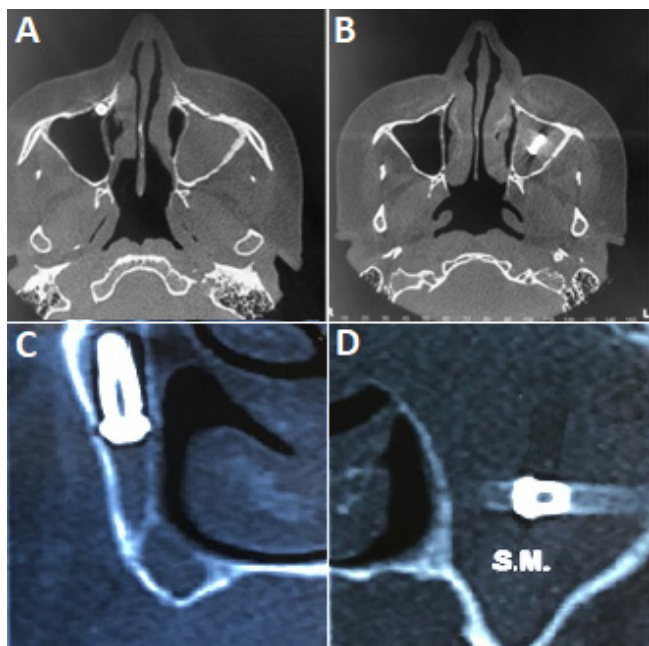
Patient J.F., female, 44 years old, sought the Department of Oral and Maxillofacial Surgery at Positivo University, with recurrent headache and recurrent sinusitis. In the anamnesis, the patient reported having been submitted to the installation of nine implants in the maxilla fifteen years ago, without postoperative follow-up. She also reported that all implants had been lost over the years.

At extraoral physical examination, patient presented no changes. In the intraoral examination the presence of lower anterior teeth with severe periodontal involvement was observed and the upper region presented a poorly adapted prosthesis, supported by a single implant.

Imaging examinations were requested for evaluation (panoramic radiography and computerized tomography of the maxilla) which showed displaced implants in bilateral maxillary sinus, besides radiopaque and dense image in the left maxillary sinus (figures 1 and 2).



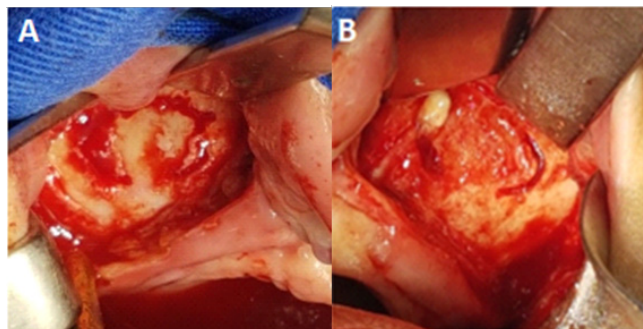
**Figure 1** - Pre-operative panoramic radiography showing bilateral displacement of implants in the maxillary sinus



**Figure 2** - Computerized tomography A-B) Axial views showing displaced implants and sinusitis on the left sinus C-D) right and left coronal views, respectively

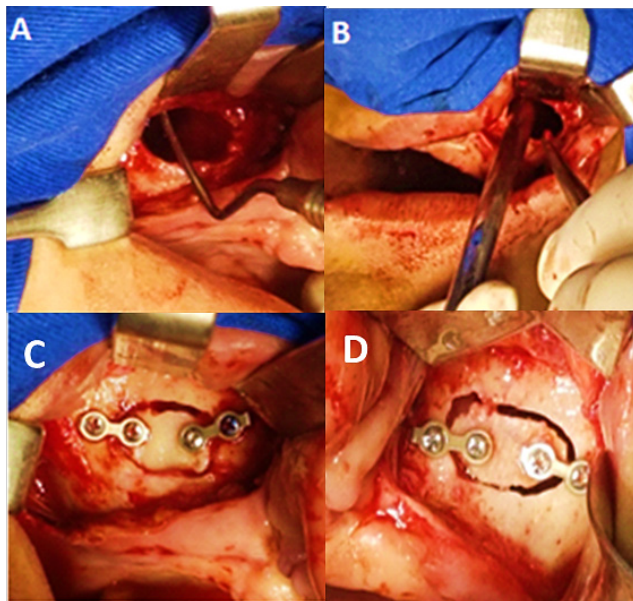
Based on these data, the proposed treatment plan was the removal of displaced implants through the access of Caldwell Luc and sinusotomy on the left under general anesthesia. A bilateral incision at the fund of the maxilla vestibule was performed, followed by mucoperiosteal detachment, evidencing the anterior wall of both maxillary sinuses. Afterwards, an osteotomy was drawn in the area. On the left side there was drainage of purulent secretion (figures 3A and 3B). Then, two titanium plaques of the 1.6 mm, two-hole system were placed, one at each end of the bone window, securing the

screws only at the end that would be removed. The perforations at the other ends were also performed so that the window, which will be removed for removal of the implant, was repositioned in the same place to avoid anatomical defects.



**Figure 3** - Caldwell-Luc technique to access the anterior wall of maxillary sinus. A) right side osteotomy; B) left side osteotomy

Afterwards, the curettage of the entire cavity of the maxillary sinus was performed, the implants removed and irrigated abundantly with saline solution. Finally, the bony windows were fixed in position, following the markings previously done (figures 4, 5 and 6). The incision was sutured with Polyglactin thread.



**Figure 4** - Curettage around the lesion. A) right side; B) left side. Bone windows already fixed in position with the titanium plaques and screws. C) right side; D) left side



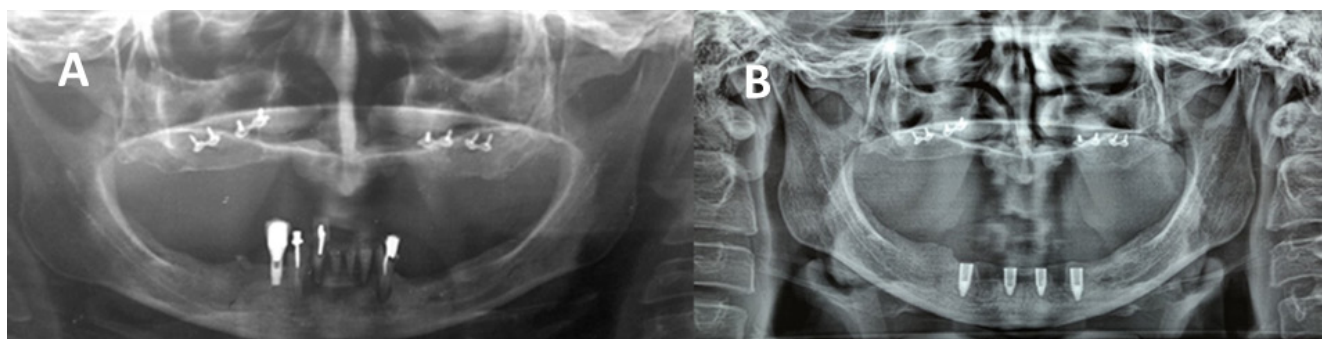
**Figure 5** - Removed implants

In the postoperative period, Amoxicillin 850mg with Potassium Clavulanate 125 mg every 12 hours

for 10 days was prescribed, Nimesulide 100 mg every 12 hours for 5 days and Dipyron Sodium 500 mg every 8 hours for 5 days. Use of nasal spray (oxymetazoline hydrochloride 0.5 mg / ml) was also prescribed every 8 hours for 7 days.

At 30 days, the patient underwent panoramic radiography for postoperative control (figure 6A), showing the normal aspect of the maxillary sinuses, which means that the surgery occurred as expected.

Three months after surgery, the patient had to remove fibrosis from the gingival tissue, under local anesthesia, to obtain a better adaptation of the provisional total prosthesis. Then, the patient was submitted to a new surgical phase, for the extraction of the remaining lower teeth and the installation of four lower implants (figure 6B) for the protocol prosthesis confection.

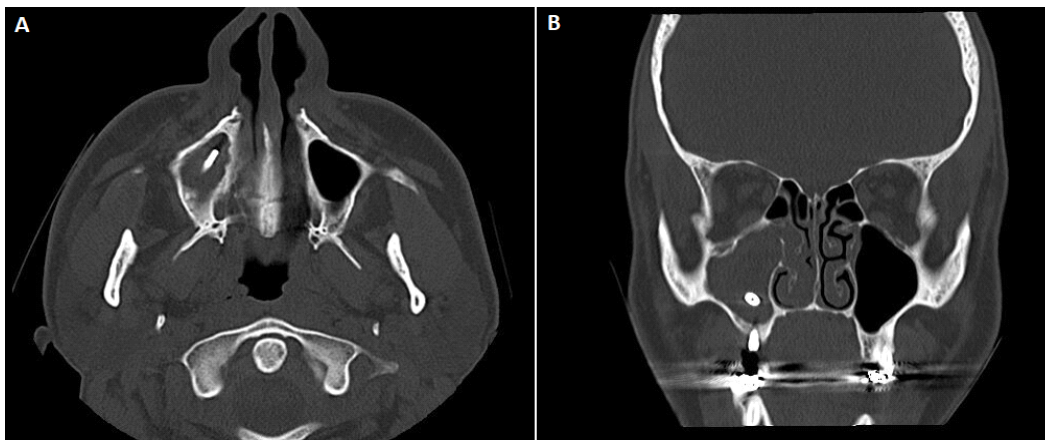

**Figure 6** - A) Pos-operative panoramic radiography; B) panoramic radiography with the installation of lower implants

Patient has been followed up, with no pain, and no infection signs, waiting for the bony healing time for the superior prosthetic rehabilitation.

## Case presentation 2

Patient C.G.A., 42 years old, referred to the Oral and Maxillo Facial Surgery Service for the removal of an implant in the right maxillary sinus. Patient reported installation of implant in the area of the first maxillary molar around nine months ago. Since the reopening surgery, performed a month before the consult, the patient has developed a severe sinusitis. As a treatment antibiotic therapy amoxicillin isolated was prescribed, followed by amoxicillin 500 mg + clavulanate 125 mg, without improvement of symptoms. A tomography of the sinuses was requested, in which the displacement of the implant to the right maxillary sinus and radiopaque and dense area was diagnosed, which characterizes sinusitis (figures 7A and 7B).

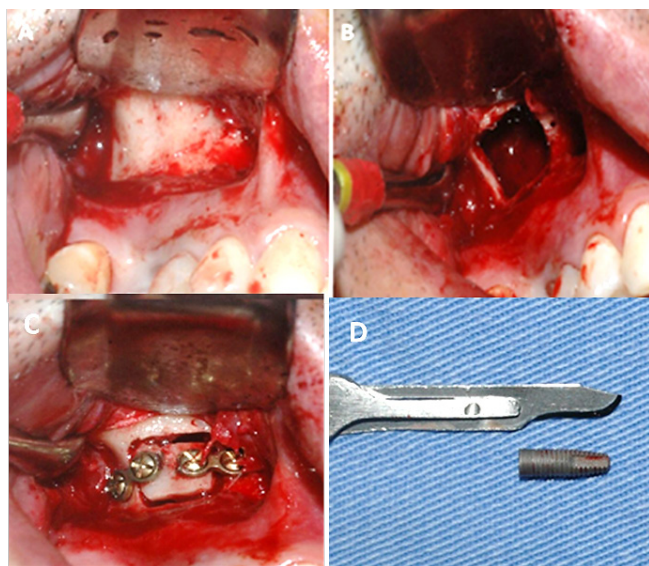


**Figure 7** - Computerized tomography. Axial view (A) and coronal view (B) indicating the implant displaced to the right side

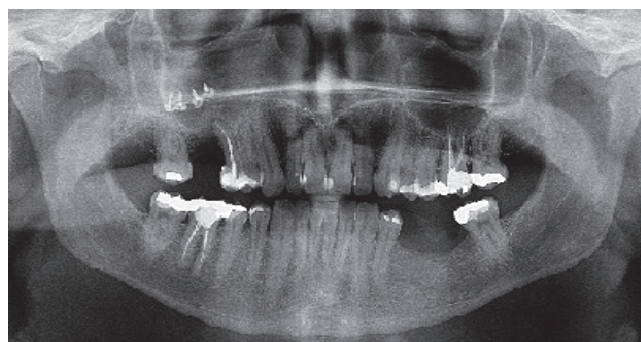
The proposed treatment plan was the removal of the implants through the modified access of Cardwell Luc sinusotomy on the right side. Prior to the surgical procedure, the patient was dosed with Levofloxacin 500 mg every 12 hours for seven days and Prednisone 10 mg daily for seven days. The implant was then removed under local anesthesia. An incision was made in the vestibule fund of the maxilla on the right side, followed by mucoperiosteal detachment, evidencing the anterior wall of the maxillary sinus. Afterwards, the osteotomy was drawn in the region, with drainage of purulent secretion (figures 8A and 8B).

Two titanium fixation plaques of the 1.6 mm, two-hole system were placed, one at each end of the bone window, securing the screws only at the end that would be removed. The perforations at the other ends were also performed, so that the window that will be removed for removal of the implant was repositioned in the same place, to avoid anatomical defects. Afterwards, the curettage of the entire cavity of the maxillary sinus was performed, the implants removed, and the region irrigated abundantly with saline solution. Finally, the bony windows were fixed in position, following the markings previously done (figures 8C and 8D).

Thirty days after surgery, the patient showed no sinusitis symptoms and good healing (figure 9).



**Figure 8** - Caldwell-Luc Technique to access anterior wall of maxillary sinus. A) osteotomy; B) window for the access of the implant; C) bony window already fixed in position with the titanium plaque and screws; D) removed implants



**Figure 9** - Pos-operative panoramic radiography

## Discussion

Dental implant displacements occur more often during procedures in the posterior region of the maxilla. This region is generally characterized by low bone density and quality, rapid resorption of the alveolar ridge, sinus pneumatization, which

may lead to lack of stability and sinus perforation with displacement of implants [8]. The causes of the displacements may be surgical inexperience, excess of force during the manual installation of the implant and the possible presence of oral sinus communication [2, 20]. This type of event can be classified as an accident, that is, when it occurs during surgery, or as a complication, when it occurs after surgery, varying from hours to years [3].

When suspected implant displacement, appropriate diagnostic exams should be requested in order to develop the appropriate treatment plan. It is essential that imaging exams be recent because of the uncertain location of the implants. It was noted, in one of the cases in question, that the implants moved into the maxillary sinus, changing position spontaneously. The plan for a correct treatment to remove the displaced implants should be according to the size and location of the foreign body and the condition of the maxillary sinus [17]. The treatments reported in the literature for the removal of maxillary sinus dental implants are aspiration through an alveolar bone defect, Caldwell-Luc technique, functional endoscopic sinonasal surgery (FESS) and transoval endoscopic access through canine fosse [18].

The least invasive treatment is endoscopic surgery, which has the main advantage of being more conservative [16], not impairing the soft tissues, respecting the integrity of the maxillary sinus, if [4, 6, 8, 9, 12]. It is indicated with the purpose of minimizing complications, since the surgical time is reduced, having a good postoperative recovery [12]. Another advantage of endoscopic surgery, apart from the removal of the implant from the maxillary sinus, is the creation of an adequate patency of the natural maxillary ostium [19]. Other ways of treatment also exist such as removal with an endoscopic probe through the lateral wall of the maxillary sinus and creation of a bony cover of the anterior wall of the maxillary sinus [11, 21]. Despite all its advantages, isolated FESS is not fully effective in removing larger materials and also has a greater difficulty in removing materials located posteriorly and inferiorly in the sinus [12, 13]. The Caldwell-Luc approach is best suited to remove these objects [13]. In the reported cases, the modified Caldwell-Luc technique was chosen due to the time and location of the implants in the maxillary sinus and the secretion caused by sinusitis present. To make the surgery more conservative, it was decided to reposition the anterior wall of the maxillary sinus, with titanium plates, as it helps

the repair of the maxillary sinus, accelerating the posterior rehabilitation of the patient.

The Caldwell-Luc approach is most often chosen to remove the displaced implants to the maxillary sinus because it is an approach that allows a better visualization of the surgical area which facilitates the removal of objects in this region, is indicated to remove objects that cannot be removed endoscopically due to their size or excessive displacement [15].

## Acknowledgements

The authors declare there are no conflicts of interest. This case report did not receive any specific grant from funding agencies in the public, commercial, or not-for-profit sectors.

## References

1. Aguiar R, Júnior AN, Hernandez AG, Pinto J, Ciprandi MT, Gassen H. Surgical removal of an instrument accidentally displaced into the maxillary sinus during implant installation. *RFO*. 2007;12(3):65-8.
2. Anavi Y, Allon DM, Avishai G, Calderon S. Complications of maxillary sinus augmentations in a selective series of patients. *Oral Surg Oral Med Oral Pathol Oral Radiol Endod*. 2008;106(1):34-8.
3. Brook I. Sinusitis of odontogenic origin. *Otolaryngol Head Neck Surg*. 2006;135(3):349-55.
4. Chiapasco M, Felisati G, Maccari A, Borloni R, Gatti F, Di Leo F. The management of complications following displacement of oral implants in the paranasal sinuses: a multicenter clinical report and proposed treatment protocols. *Int J Oral and Maxillofac Surgery*. 2009;38(12):1273-8.
5. Chiapasco M, Zaniboni M, Rimondini L. Dental implants placed in grafted maxillary sinuses: a retrospective analysis of clinical outcome according to the initial clinical situation and a proposal of defect classification. *Clin Oral Implants Res*. 2008;19(4):416-28.
6. El Charkawi HG, El Askary AS, Ragab A. Endoscopic removal of an implant from the maxillary sinus: a case report. *Implant Dent*. 2005;14:30-5.

7. Gassen HT, Biancon Filho LA, Ciprandi MA, Silva-Júnior AN, Hernandez PA. Deslocamento de corpo estranho para o seio maxilar: fatores etiológicos e remoção pela técnica de Caldwell-Luc. *Revista Odontológica do Brasil-Central*. 2007;16(42).
8. González-García A, González-García J, Diniz-Freitas M, García-García A, Bullón P. Accidental displacement and migration of endosseous implants into adjacent craniofacial structures: a review and update. *Med Oral Patol Oral Cir Bucal*. 2012;17(5):769-74.
9. Kitamura A, Zeredo JL. Migrated maxillary implant removed via semilunar hiatus by transnasal endoscope. *Implant Dent*. 2010;19:16-20.
10. Kluppel LE, Santos SE, Olate S, Freire Filho FW, Moreira RW, de Moraes M. Implant migration into maxillary sinus: description of two asymptomatic cases. *Oral Maxillofac Surg*. 2010;14(1):63-6.
11. Mantovani M, Pipolo C, Messina F, Felisati G, Torretta S, Pignataro L. Antral retriever and displaced dental implants in the maxillary sinus. *Journal of Craniofacial Surgery*. 2011;22(6).
12. Nakamura N, Mitsuyasu T, Ohishi M. Endoscopic removal of a dental implant displaced into the maxillary sinus: Technical note. *Int J Oral Maxillofac Surg*. 2003;33:195-7.
13. Nemeč SF, Peloschek P, Koelblinger C, Mehrain S, Krestan CR, Czerny C. Sinonasal imaging after Caldwell-Luc surgery: MDCT findings of an abandoned procedures in time of functional endoscopic sinus surgery. *Eur J Radiol*. 2009;70:31-4.
14. Raghoobar GM, Vissink A. Treatment for an endosseous implant migrated into the maxillary sinus not causing maxillary sinusitis: case report. *Int J Oral Maxillofac Implants*. 2003;18(5):745-9.
15. Rebouças D, Lima RR, Rocha Junior WG, Assis AF, Zerbinati LP. Sinusite crônica decorrente de corpo estranho em seio maxilar. *Revista Bahiana de Odontologia*. 2014;5(2):131-6.
16. Sgaramella N, Tartaro G, D'Amato S, Santagata M, Colella G. Displacement of dental implants into the maxillary sinus: a retrospective study of twenty-one patients. *Clin Implant Dent Relat Res*. 2016 Feb;18(1):62-72.
17. Shankar, L. Atlas de imagem dos seios paranasais. Ed. Revinter; 1997.
18. Tavares R, Nogueira A, Bezerra M, Gonçalves E, Sampieri MB. Late displacement of a dental implant into maxillary sinus. *Braz J Otorhinolaryngol*. 2014;80(4):359-61.
19. Tilaverisis I, Lazaridou M, Dimitrakopoulos I, Lazaridis N, Charis C. Displacement of three dental implants into the maxillary sinus in two patients. Report of two cases. *Oral Maxillofac Surg*. 2012;16(3):311-4.
20. Varol A, Türker N, Göker K, Basa S. Endoscopic retrieval of dental implants from the maxillary sinus. *Int J Oral Maxillofac Implants*. 2006;21(5):801-4.
21. Wildmark G, Ekholm S, Borrmann H, Grangård U, Holmberg K. The use of a bone lid to close the anterior wall defect after surgery in the maxillary sinus. *Swedish Dental Journal*. 1992;16(5):173-82.